

High School of Economics and Management
(Bratislava, Slovakia)
Higher State Educational Establishment of Ukraine
“Bukovinian State Medical University”
(Chernivtsi, Ukraine)

Natural Science Readings

abstracts book
(May 30-31, 2019, Bratislava)

Bratislava, 2019

UDC 5(063)

Natural Science Readings: abstracts book. May 30-31, 2019.
Bratislava, 2019. – 160p.

Editors-in-chief:

Prof. Viera Cibakova; MD, prof. T.M. Boychuk; MD, prof. O.I. Ivashchuk; MD, prof. R.Ye.Bulyk; PhD. I.V. Gerush; MD, Prof. Vladimir Krcmery MUDr, PhD Yu.V. Tovkach, PhD D.V. Proniaiev, Asso. prof., CSc Nadya Dubrovina, St. Elisabeth University of Health Care and Social Work, Boguslaw Blicharski,

Special thanks: foundation "Zlote Serce" (Boguslaw Blicharski),
InterGing (Hameln, Germany)

ISBN 978-80-89654-46-8
EAN 9788089654468

© Bratislava, 2019

Aleksandrova K.V., Mykhalchenko E.K., Vasylyev D.A.
**ENERGOTROPIC PROPERTIES OF 7-SUBSTITUED
DERIVATIVES OF 3-BENZYL-8-PROPYLXANTHINES AS
POTENTIAL ORGANOPROTECTIVE DRUGS**

Zaporizhzhia State Medical University,

Department of biological chemistry, Zaporizhzhia

Hyperproduction of active forms of oxygen is one of the main factors of inhibition of bioenergetics processes during ischemic cell damage. Chemically such forms of oxygen can cause various functional and morphologic modifications in aerobic creatures. Defensive mechanisms against oxidative damage may be involved in the etiology of pathologic processes induced by oxidative stress. Different antioxidant substances are used in treatment of these conditions. This is due to the development of the oxidative modification of enzymes in the respiratory chain of mitochondria, which leads to the development of mitochondrial dysfunction, restriction of the ATP synthesis and energy imbalance of cells. Despite the wide range of organoprotective drugs, medicine is in great need of drugs that would have an energotropic effect, reduce the manifestations of mitochondrial dysfunction and normalize the imbalance of the adenine nucleotides pool. The goal of our work was to study the energotropic properties of newly synthesized 7-substituted derivatives of 3-benzyl-8-propylxanthines – potential organoprotective agents.

The experiment was performed on white, outbred rats using the model of acute myocardial infarction, which was reproduced by the stepwise administration of isadrine and pituitrine. The content of adenine nucleotides in myocardial tissues was determined by thin layer chromatography. For an in-depth analysis of energy supply of cardiomyocytes in ischemia conditions, we calculated the following energy metabolism indices: energy charge, energy potential, comparison factor, phosphorylation index and thermodynamic breath control index. Because of the research on the model of acute myocardial infarction, compounds with pronounced energotropic properties were determined, which, by main pharmacological effect, exceeded the reference drug – mildronate.

Bambuljak A.V., Boichuk O.M.

SURGICAL FEATURES OF FRONTAL SINUSES

Higher State Educational Establishment of Ukraine “Bukovinian State Medical University”, Department of Surgical Dentistry and Maxillofacial Surgery

For many years the questions of anatomy, topography and functional relationships of the facial skull structures remained open and was being resolved along with the development of technical progress. Diagnostics and treatment of frontal sinuses diseases is a more complex and difficult task compared with other diseases of the sinuses. There is a lack of knowledge of specialists with modern anatomy-physiological and instrumental methods of their study and treatment. However, one of the intricate and controversial questions about the structure of the sinuses is the question of the topographical anatomy of the fronto-nasal conjugation and surrounding structures.

The development of endoscopic intracranial surgery requires a detailed spatial understanding of the three-dimensional structure of the nasal cavity and sinuses. When performing functional endoscopic interventions on sinuses, it is necessary to take into account the peculiarities of the structure of their mucous membranes, most of all - in such key areas: the osteomeatal complex and the sphenoid recess. Endoscopic and microscopic surgery of nasal sinuses has shown that there are no excessive elements in the nasal cavity and the sinuses. Each anatomical structure has its own physiological purpose. In the surgery of the frontal sinus, the structure of the fronto-nasal conjugation is of great importance, since the main direction of manipulation and operations is performed through the place of the frontal sinus and nasal cavity connection. On the one hand, surgical intervention leads to a violation of the flashing field and mucocellular clearance, and on the other hand – without surgical intervention, the aeration of the sinuses does not restore, and without this it is impossible to cure the patient. At present, it has been proven that surgical interventions on the sinuses, including the frontal ones, based on the position on their protective function, should be preferred to thrifty organo-preserving operations.

Boichuk O.M., Bambuljak A.V.

EWING'S SARCOMA

Higher State Educational Establishment of Ukraine "Bukovinian State Medical University", Department of Surgical Dentistry and Maxillofacial Surgery

Ewing's sarcoma (ES) is a malignant solid tumor. Most often it grows in bones. Rarely, it can grow in soft tissues, that is, in connective tissues, in the adipose, muscle tissues or peripheral nerves. The disease is named after the cancer researcher James Ewing from New York (1866-1943), who first described this tumor in 1920.

Ewing's sarcoma is rare. It's morbidity in developed European countries is just 3 out of 1,000,000 children under the age of 15. Of the 1,000,000 adolescents and young people aged 15 to 25 years old, the disease affects 2,4 individuals. Most of all patients are children and adolescents between the ages of 10 and 20. Peak falls on the age of 12-17 years. However, the Ewing's sarcoma can grow in infants and young children, school children, and even in elder people. Young and adult males are more affected by this disease than females (the ratio is 1,3:1).

According to the National Cancer Institute, the only histogenesis of tumors that are derived from primary neuroectodermal cells, with a predominant lesion of bone, is up to 22% of all primary bone tumors in children. The age-old peak of the disease is found out approximately in the second decade of life, the frequency of occurrence – 0,6-1 case per 1 million of population. Among those who fell ill, the male/female ratio is 1.7: 1.

During the ES disease, the primary bone defect is observed in 87% of cases. Limb bones and trunk are affected in 53% and 47% respectively. For localization in the predominant localization of CU of limb cases). Trunk lesions are 45% represented by pelvis tumors. Primary lesions of the chest bones, spine and skull are 34%, 12% and 9% respectively. Distal diaphysis areas are most common localizations of limb's ES (58% of cases). In 74% of primary patients, the tumor is localized in trunk, mostly in within the chest.

Considering a high risk of generalization, this group of tumors is considered as a systematic disease. 20-23% of tumors are primary metastatic forms, about 89% of patients have micro-metastasis. Typical is lung metastasis (38% -45%), other bones (31%), bone marrow (11%), lymphatic nodes (7%). Metastasis type is mainly hematogenous

Dmytrenko R.R., Honcharenko V.A.

PERIODONTAL DISEASES – MODERN PROBLEM STATE

Higher State Educational Establishment of Ukraine “Bukovinian State Medical University”, Department of Surgical Dentistry and Maxillofacial Surgery

In recent years, interest in the structures of the walls of the oral cavity and their functions continues to grow, due to the fact that periodontal disease is one of the most common diseases in dentistry. Periodontal disease afflicts more than 80% of the adult population and almost the same percentage of children. Despite the fairly large number of experimental and clinical studies, the problem of periodontal diseases remains extremely relevant for Ukrainian and world dentistry. Among all periodontal diseases, inflammation is found in 90-95% such as gingivitis and periodontitis. Gingiva, as part of the periodontium, is an adaptive part of the human and animal body, which undergoes constant influence of genetic, epigenetic, intraorganic and external factors of influence.

The epithelial layer of the gum divides the internal periodontal environment from its external environment into the oral cavity. This internal environment has its dynamic constancy, which has recently received the name periodontal physiological homeostasis. The epithelial layer of the gum provides a tight closure of the internal periodontal space from the external environment and is the first line to protect the periodontal homeostasis, it is for these reasons that gum is a part of the periodontium that deserves priority attention and study. There is a dynamic balance between the homeostasis of the oral cavity and the periodontal homeostasis. Changing qualitative or quantitative composition in one of them is accompanied by changes in another. Changes of the integrity of the epithelium of the gum (mechanical, chemical, bacterial and other factors) leads to a change of the physiological barrier, its natural continuity and creates direct contact between the internal and external periodontium, that is, violates the physiological periodontal homeostasis. This is precisely the reason that causes periodontal disease and makes patients to visit a dentist, whose task is to restore the physiological homeostasis of the periodontal disease.

Kavun M.P.

**THE DEVELOPMENT OF THE HEPATO-DUODENAL
LIGAMENT IN THE 6 – 10 MONTHS HUMAN FETUSES**

*Higher State Educational Establishment of Ukraine “Bukovinian State
Medical University”*

Department of human anatomy named after M.H. Turkeyvych

In the middle of the fetal period (6-7 months of the intrauterine development) in fetuses of 188,0 - 268 mm of PCL the hepato-duodenal ligament continues to grow in size, and its length is particularly equal with its width: the length grows from 5,0 mm to 10,0 mm, the width – from 4,0 mm to 10,0 mm.

The branches of the proper hepatic artery are located most superficially near the hepatic portal area, in front of the branches of the portal hepatic vein. The branch of the common hepatic duct is located deeper from the branches of the portal hepatic vein.

Thus, in fetuses of 8 - 10 months of development (fetuses of 270 – 375 mm of PCL) the length of the ligament is 6 – 10 mm, the width – 9 – 12 mm.

In its upper portion between the peritoneal layers there are cystic and common hepatic ducts, proper hepatic artery and portal hepatic vein. The common bile duct is located in the inferior portion of the ligament, to the left from it on the distance of 0,7 - 0,9 mm – the common hepatic artery with its branches is located. Backward from the above structures directly close to the common bile duct on the distance of 0,2 - 0,3 mm to the left the portal hepatic vein is located.

The hepato – duodenal ligament in neonates is of a trapezoid shape, turned to the hepatic portal area by its wide base. The length is from 8,0 - 16,0 mm, the width – 12 - 18 mm.

The cystic duct is located in the upper portion of the ligament close to its right border, the common hepatic ducts – to the left. The branch of the proper hepatic artery occupies the outside left position. The portal hepatic vein is located backwards from the common hepatic duct.

Kavun M.P.

**MORPHOGENESIS OF THE HEPATO-DUDENAL LIGAMENT
IN THE 3 – 5 MONTHS HUMAN FETUSES**

*Higher State Educational Establishment of Ukraine “Bukovinian State
Medical University” Department of human anatomy named after M.H.
Turkevych*

We have studied the morphogenesis of the hepato-duodenal ligament in fetal period of human ontogenesis. 15 preparations of human fetuses of different age groups were studied by the methods of histology, making image reconstruction, by the methods of usual and subtle dissections and morphometry.

In fetuses of 3 – months intrauterine development the length of the hepato – duodenal ligament ranges from 3,5 to 4,5 mm, width – from 4,0 to 5,0 mm. Clear outlines of the bile ducts and blood vessels are seen through its anterior layer surrounded by a thin layer of the cellular tissue. Cystic and common hepatic ducts, proper hepatic artery with branches originating from it to the liver and gallbladder, and portal hepatic vein are located in the cranial portion of the ligament.

The common bile duct, portal hepatic vein, common hepatic artery with vessels originating from it to the stomach, duodenum and pancreatic head are found in the caudal portion of the ligament.

In fetuses of 4 - 5 months of intrauterine development (fetuses with 79,0 –185,0 mm of PCL) hepato – duodenal ligament is well – formed, trapezoid in shape, turned to the hepatic portal area by its wide base. The length of the ligament is from 3,0 to 9,0 mm, width – from 3,0 to 7,0 mm. It should be noted that at the beginning of the fetal period the largest formation among the tubular structures of the above ligament is the portal hepatic vein.

The length of the trunk of the vessel ranges from 4,0 to 6,0 mm, in 5 - month fetuses – from 5,0 to 8,0 mm. The diameter of the vessel is from 1,0 to 1,4 mm.

Kushnir O.V., Fundiur N.M., Grachova T.I., Iftoda O.M.
**HYGIENIC EVALUATION OF QUANTITATIVE AND
QUALITATIVE COMPOSITION OF THE DAILY NUTRITION
RATION OF CHILDREN AT THE PRESCHOOL INSTITUTIONS
OF CHERNIVTSI**

*Higher State Educational Establishment of Ukraine
«Bukovinian State Medical University»,
Department of Hygiene and Ecology, Chernivtsi*

The problem of children's health under contemporary conditions is of a special importance, as economic and social complications as well as ecological environmental conditions influence upon the rising generation. It is explained by a high sensitivity of children to harmful environmental factors. According to all the WHO data available an alimentary factor is one of the leading determinants of health. An adequate diet is one of the major factors determining the physical development of children, optimal functioning of all the organs and systems, their adaptive-compensatory possibilities and the level of children's health.

The purpose of the research is to study and hygienic evaluation of the quantitative and qualitative composition of the daily dietary rations of preschool children attending children's educational establishments.

The state of organized food supply of children attending nine preschool institutions in Chernivtsi was examined by means of the calculation method by copying the data during 10 days from the menu according to the seasons of the year. Then an average amount of products per one child a day was determined and compared with the recommended one. Energy value of food and the content of main nutrients in it were detected by means of specially elaborated program compiled on the basis of I.M. Skurykhin's reference tables. Qualitative and quantitative indices of children's diet were estimated according to the national regulations "On Approval of Nutrition Standards in Educational and Children's Recreation Facilities" (2004) and "On Approval of Norms of Physiological Needs of the Population of Ukraine in the Basic Nutrients and Energy" (2017).

The nourishment of children in preschool institutions of Chernivtsi is organized according to group principle: practically healthy children of a certain group get similar by its volume and chemical content food

corresponding to average physiological requirements of their organisms in the main nutrients and energy.

The energy value of rations at three meals a day was $1486,98 \pm 102,38$ kcal, which provided 81,6-93% of the recommended daily caloric value (1700 kcal). The volume of food is distributed according to the time of meal: breakfast – 20-25%, lunch – 35-40 %, afternoon snack – 10-15% out of daily energy food value.

The analysis of the menu showed increase of consumption of the food products, which are high-caloried, reach of simple carbohydrates and are poor of dietary fiber. In particular, there was more than required white bread in children's diet (45% more), and rye bread was absent. Excess of cereals, beans, macaroni (37,8 % more) and pastry (13,3% more) should be noted. The content of potato was less then recommended one by 21,6%, and other vegetables (beet, carrot, cabbage, squash, onion) - by 1,3%. Vegetables were usually consumed in food after heat treatment, which reduced their nutritional and biological value At the same time, there was a significant deficit of fresh fruit (by 75%) and dried fruit (by 50%).

There was insufficient content of products found that are the sources of complete proteins, fats of vegetable and animal origin. In particular, the content of meat and meat products were less then recommended one by 30%, fish and fish products - by 24,4%, eggs - by 40%, milk and dairy products - by 18,8%, cottage cheese and cheese - by 33,3% and 40%, respectively. The average daily amount of butter was within the recommended one and the content of sunflower oil was lower by 22,2%.

The ratio of proteins, fats and carbohydrates did not correspond to the recommended 1:1:4 due to reducing the fat quota and exceeding the quota of carbohydrates in daily rations. The content of animal proteins in the diet was $46,8 \pm 2,18\%$ relative to their total, which is lower than the recommended one (60%). The content of vegetable fats was $16,6 \pm 0,32\%$, which is lower than the recommended (20% of the total amount of fats). The quantity of monounsaturated fatty acids provided $13,6 \pm 0,82\%$ of the energy value of the diet, what is slightly higher than the recommended (10%) and the content of polyunsaturated fatty acids provided $5,0 \pm 0,08\%$ of the energy value of the diet, what is twice less recommended. Simple

carbohydrates content was $41,0 \pm 2,8\%$ relative to their total amount, what is two times higher than those recommended norms.

Unbalanced diet is one of the risk factors for the decreasing the body resistance to unfavourable environmental factors and developing of functional disorders in children's health, which may further lead to the formation of somatic pathology.

The dietary ration of preschool children needs the such correction: to increase the content in the diet of products, which are sources of animal protein (meat and meat products, eggs, milk and dairy products, cheeses), of fats of vegetable origin (vegetable oils, seeds, nuts), of ω -3 polyunsaturated fatty acids (sea fish, fish products), of fibers (rye bread, fresh fruits and uncooked vegetables); to increase consumption of buckwheat, oat, barley grains due to reduction in the diet of macaroni and confectionery products, portion of wheat bread and fried foods. Analysis of the daily children's diets at preschool institutions of Chernivtsi showed that their food was diverse, the order and intervals between meals were kept, as well as the sequence of taking dishes and distribution of energy value. An insufficient content of products that are sources of complete proteins, animal and vegetable fats, fibers was established. The ratio of proteins, fats and carbohydrates did not correspond to the recommended due to reducing the fat quota and exceeding the quota of simple carbohydrates in daily rations. The obtained results and conclusions formed the basis recommendations for correction of actual children's diets at preschool institutions of Chernivtsi.

Shvygar L.V., Khlunovska L.Yu.,
**STRUCTURAL CHANGES OF MYOCARDIUM IN CHILDREN
WITH ARTERIAL HYPERTENSION**

*Department of Pediatrics and Medical Genetics
Higher State Educational Establishment of Ukraine
“Bukovinian State Medical University”, Chernivtsi, Ukraine*

Topicality.The echocardiographic (EchoCG) method of examination is one of the most available methods of screening heart diseases, which reveals as structural features of organs disturbance of systolic and diastolic functions of the heart. Aim of study: to value EchoCG parameters of the heart in children with arterial hypertension (AH).

Material and methods.It was examined 50 children with AH of 10-17 year old which were consulted in Regional Children's Consultative Polyclinic. There were 32 boys (64 %) and 18 girls (36 %). All children were divided into 2 groups: the first one consist of children with AH (n=26, 22 boys (84,6 %) and 4 girls (15,4 %)); the second group included children with AH and overweight (n=24, 16 boys (46,6 %) and 8 girls (33,3 %)).

By evaluation of systolic function of the left ventricle according to EchoCG in children of the second group were observed statistically significant ($p < 0,05$) higher values of some parameters: systolic volume of blood, thickness of the posterior wall of the left ventricle in the systole, diameter of the left ventricle in the systole and diastole, hyperkinesia of the interventricular septum in comparison with the same data of children in the first group. The expressed intergroup differences of structural parameters such as ejection fraction, fractional shortening, diameter of the right ventricle, thickness of the posterior wall of the left ventricle in the diastole in children with AH in comparison with children of the second group were not admitted.

The analysis of hemodynamic parameters, based on the EchoCG method in children with AH, will allow them to be considered as additional diagnostic criteria in patients with a high risk of dystrophic changes in myocardium, where there is a risk of AH. EchoCG is a highly sensitive method of assessing the state of the heart, which allows to detect structural and functional changes of the myocardium on early stage of pathology and analyze their dynamics in the process of observation and treatment.

Shvygar L.V., Khlunovska L.Yu
**EVALUATION OF BLOOD SUPPLY TO THE BRAIN IN
CHILDREN WITH SYNDROME OF VEGETATIVE-VASCULAR
DYSFUNCTION**

*Department of Pediatrics and Medical Genetics
Higher State Educational Establishment of Ukraine
“Bukovinian State Medical University”, Chernivtsi, Ukraine*

Actuality of learning of the syndrome of vegetative-vascular dysfunction in childhood is the prevalence and ongoing increase in the number of patients. The main complaint is headache, but it is the result of a number of pathological changes that had place before. The most common cause of headache is increased intracranial pressure, which in turn is caused by vascular disorders.

The aim of study: to explore the presence of spine pathology and signs of increased intracranial pressure in children with the syndrome of vegetative-vascular dysfunction.

Material and methods: it was examined 64 children in age from 8 to 17 year old suffering from the syndrome of vegetative-vascular dysfunction (41 girls and 23 boys, middle age – $14,1 \pm 2,8$ years). Echoencephalography and ophthalmological examination were conducted to establish the signs of increased intracranial pressure in children with a headache. It was evaluated constriction and sinuosity of the arteries and veins dilatation during ophthalmological examination of the ocular fundus. Patients were examined by orthopedist and passed X-ray examination of the cervical spine.

Analyzing the data of physical examination of children with the syndrome of vegetative-vascular dysfunction we found that all of them complained on headache. Other signs of increased intracranial pressure such as nausea and vomiting were observed in 29 children (45,3 %). Echoencephalographic data of increased intracranial pressure were found in 47 children (73,4 %). Ophthalmological examination confirmed the signs of increased intracranial pressure in 39 children (60,9 %). In 38 children (59,3 %) was determined spine pathology (by orthopedist and additional X-ray examination). There were found some X-ray cervical spine changes such as osteochondrosis of the cervical spine and functional

blocks of the cervical vertebrae and scoliosis, which can lead to a decrease of blood supply of the brain through the vertebral arteries.

Headache as a symptom of the syndrome of vegetative-vascular dysfunction was the initial clinical sign of increased intracranial pressure caused by spine pathology.

Lavriv L.P.

DEVELOPMENT OF THE HUMAN PAROTID GLAND IN FETUSES

*Higher State Educational Establishment of Ukraine
«Bukovinian State Medical University» Chernivtsi City, Ukraine,
Department of Anatomy, Topographic Anatomy and Operative
Surgery*

Formation of the organs is a very complicated process which is not definitively studied nowadays. It is very important to study the structure of the organs and systems in association with the basic processes of morphogenesis on the basis of the findings of embryogenesis. The study of the development and forming of the topography of the parotid gland during the prenatal period human ontogenesis is of great importance for integral understanding of the structural –functional organization of the salivary apparatus and the oral cavity on the whole.

The study of variant anatomy and topographical and anatomical features of the human parotid gland on 26 fetuses with 130,0-375,0 mm of crown to rump length by means of fine preparation under the control of a binocular magnifier: macro- and microscopy, morphometry and 3D reconstruction.

According to the results of computer 3-D modeling of the parotid glands of the fetuses aged 6-10 -month, the most practical is a 3-D description as the trilateral pyramid, which lies in the retromandibular fossa and in the lateral area of the face, turned with its base to the zygomatic arch, its vertex going downwards - to the angle of the mandible. 8-10 -month-old fetuses had some indurations in fascial cellular masses of the glandular bed, especially in the areas of close topographical and anatomical interrelations of organs and structures. Between the outer capsule of the gland, surrounding vascular, nerve branches and fascial formations of the investigated area in 8-10 months fetuses there are tight

adhesions that should be considered during the operative interventions within the parotid- masticatory area in newborn infants. Active application of perinatal prevention of congenital defects require sup-to-date approaches and methods of embryonic growth study.

Embryotopographic research, which takes into account specific and critical for some organs periods of their growth and some peculiarities of their interrelations with adjacent organs and structures, becomes especially important.

Kostiuk V.O., Lavriv L.P., Stratiichuk S.D.

INFORMATION ABOUT THE TOPOGRAPHIC-ANATOMICAL FEATURES OF THE MENTAL FORAMEN OF THE MANDIBLE

Higher State Educational Establishment of Ukraine

«Bukovinian State Medical University» Chernivtsi City, Ukraine

Department of Anatomy, Topographic Anatomy and Operative Surgery

Over the past few years, the use of highly effective modern technology in maxillofacial surgery had greatly enhanced the effectiveness of eliminating various anomalies and deformations that appear in the facial part of the head. For the doctors that are experts in this area, close attention focused on knowledge of the size, shape and topography of the mental foramen (MF) of the mandible, which is the place where the branch out of the trigeminal nerve.

According to the literature, the distance from the mandible foramen to the MF in adults is an average of 60-70 mm, and the average diameter of the openings - $3,05 \pm 0,20$ mm MF and $3,75 \pm 0,15$ mm for the mandible foramen. The distance from MF to the angle of the mandible in adults is 64.2 ± 6.4 mm and 12.9 ± 1.6 mm to the lower edge of the mandible. In newborns, MF is located closer to the collateral edge at the level of the fangs, at a distance of 16-17 mm from the median line, and 5-6 mm from the lower edge of the mandible. MF is usually single and rarely there is one more, smaller in size. In the male, the horizontal diameter MF is greater than that of female, the average difference is 0.48 mm. The vertical dimension MF in the male is 2.8-4.2 mm, and in the female is 2.35-3.27 mm. During the study of the variability of the form of the MF, scientists founded that in dolichocephalous in 60% of cases prevail oval MF, opened to the up and back. In the mesocephalous (in 37% of cases), the shape of

a circle opens upwards, as well as a circle open forward (30% of cases) appear more often. In brachycephalic, in 50% of cases, MF is represented primarily in the form of a slit open up. There is an interdependence between the position MF and the type of skull. In the mesocephalous, the distance from the front edge to the middle line of the jaw ranges from 14 mm to 20 mm horizontally. In the dolichocephalous MF is slightly further horizontally from its anterior margin to the midline of the jaw than in the brachycephalous, with an average difference of 0.2 cm. Noticed that the difference in the distance from the anterior edge of MF to the middle line in mesocephalous and brachycephalous is 0.08 cm. As to the basis of the jaw, founded that in the dolichocephalous MF it is located at a greater distance from the base of the jaw than in brachycephalous. The difference in distances on average is 0.06 cm, and the difference in the meso- and brachycephalous in comparison is only 0.02 cm. The study of orthopantomograms showed that in general, in 85% of cases, MF is single, and in 15% cases, there is a doubling of it. The variability of the location of the main foramen is noticed, however, in 45% of the total number, the displacement of the projection shadow to the root of the first small premolar tooth is observed, in 50% - the classical location between the roots of small root teeth, in 5% - its displacement to the medial root of the first small root a tooth. In the shape of the shade, MF in 80% of cases is spherical, in 15% - cup-shaped and 5% - slit-shaped.

The study of individual patterns of structure of the facial structure of the head from the point of view of the possibilities of using the obtained data in plastic surgery, dental practice, traumatology can significantly improve diagnostics, planning and execution of various operative manipulations.

The mandibular foramen has a different size, shape and location, followed by a correlation between sex and skull type. For high-quality local conductive analgesia of the mental nerve and other surgical manipulations in the area of the facial part of the head, it is recommended to study the topographic and anatomical features of the structure of the vascular-nervous fasciculus and the location to prevent complications.

Nahirniak V.M.

ANALYSIS OF THE INVESTIGATION OF THE REDUCTION IN

PERIPHERAL VASCULAR RESISTANCE AFTER EXPOSURE OF LOW EXTREMITIES TO THE PERIODIC MECHANICAL VIBRATIONS

Department of biophysics and medical informatics

HSEE “Bukovinian State Medical University”, Chernivtsi, Ukraine

The normal blood flow circulation through human vasculature is important factor in restoration abilities of injured tissues, organs, and in maintaining the body's homeostasis.

Constrictions of the size of blood vessels caused by either plaque depositions on the vessels' walls due to atherosclerosis or change of the elasticity of blood vessels' walls with aging lead to appearance of additional load of a heart and development of hypertension. There are many therapeutic methods in treatment of hypertension. We study the nontherapeutic method of treatment of hypertension which includes exposure of patients to the periodic mechanical vibrations of the entire body. For the volumetric rate of a fluid flow Q through a pipe, we may write the following expression (Darcy's law):

$$\Delta P = Q \cdot R,$$

where ΔP is pressure difference in a pipe, and R is a hydraulic resistance. In case of the blood circulation through vessels, we may rewrite the previous relationship in the following way:

$$AP = CO \cdot PVR,$$

where AP is a mean arterial pressure, CO is a cardiac output which is equal to the product of a stroke volume and a heart rate, and PVR is a total peripheral vascular resistance. This equation shows that an elevation of mean blood pressure can only be a result of either an increase in cardiac output (CO), or an increase in total peripheral vascular resistance (PVR), or a combination of both. Besides peripheral resistance, blood vessel elasticity also affects a blood pressure. But it should be noticed that the recent studies showed that changes in arterial stiffness affect pulse pressure and not mean arterial pressure.

As one can see, in order to reduce the increase in mean blood pressure, the decrease in the peripheral vascular resistance is required. The peripheral resistance in vasculature maybe reached through three main mechanisms: increase in the blood vessel diameter, decrease in blood viscosity, or decrease in the total vessel length, L . A vessels' diameter is

actively regulated by vasomotor fibers, sympathetic nerve fibers that innervate the vessel's smooth muscle layer. PVR is primarily defined by small muscular arteries and arterioles with diameters running between 30–300 μm . According to the Hagen–Poiseuille equation, the increased effective radius of vessels may significantly reduce PVR and eventually the blood pressure:

$$\Delta AP = \frac{8\eta \cdot L \cdot CO}{\pi \cdot \Delta R^4},$$

where ΔR is a change in effective radius of blood vessels, L is an effective length of blood vessels, CO is a cardiac output, η is viscosity of blood. In our study, we measured the mean arterial systolic blood pressure before and after the short exposure of low extremities of men and women to the periodic mechanical vibrations of low frequency (12 Hz). We related the observed reduction in arterial pressure to the increase in the effective radius of blood vessels of feet. The experimental results on pressure reductions allowed making estimates for the numerical values for the increase in the effective radii of blood vessels.

Our study demonstrates the potential of a low frequency vibrational massage in improving a peripheral blood circulation, in increasing the blood flow, and in a recovery process of injured areas in tissues and organs.

David Alexander, Nazymok Ye.V., Ivanushko Ya.G.

MAIN STEPS IN CASES OF THERMAL INJURY

Higher State Educational Establishment of Ukraine “Bukovinian State Medical University”, Disaster and military medicine department, Chernivtsi, Ukraine

Improved understanding of the pathophysiology and the advances made in burn management over the past 50 years have contributed immensely to the dramatic rise in the survival and reduced morbidity from major burn injuries. The aim has always been to achieve wound healing as early as possible and to minimise the morbidity. The efforts towards this should commence right from the scene of the burn accident, at the time of first interaction between the casualty and the first responder. The care the victim receives within the first few hours after sustaining a burn injury largely determines the final outcome of the management. The

victim should be removed from the heat source and moved to a safe place. Prevent the victim from running which would only fan the flames and make them burn faster. The victim should be instructed to lie down on the floor with the burning side uppermost. As the flames always burn upwards, lying flat not only prevents the flames from involving the face, head and scalp hairs, but also prevents the fire from going around the body. The casualty should not be rolled on the ground. It can transfer the fire to previously undamaged areas and can also cause other injuries. If there is lot of smoke along with the fire: The rescuer should tie a rope around his waist so that another bystander can pull him to safety, if needed. Stay low or crawl on the floor to minimise the inhalation of the toxic fumes. The visibility is comparatively better at the floor level as the smoke, gases and hot air tend to rise. Moreover, breathing should be done through the wet handkerchief to filter out toxic particles. Put out the fire in an expeditious manner: stopping the burning process is mandatory to prevent further damage.

Romanenko M.I., Dolhikh O.P., Ivanchenko D.H., Sharapova T.A.
**SYNTHESIS, PHYSICAL, CHEMICAL AND ANTIOXIDANT
PROPERTIES OF 7-ALKYL-3-METHYLBENTYL-8-
AMINOALCANOIC ACIDS DERIVATIVES**

*Zaporizhzhia State Medical University, Department of Biological
Chemistry, Zaporizhzhia*

Lately, there is a strong interest in determining the antioxidant activity of medicinal forms and biologically active substances. This is due to the fact that it is generally accepted that one of the main causes of the most dangerous diseases is the accumulation of free radicals in the human body. Due to the harmful effects of free radicals, the walls of the vessels, membranes and lipids are oxidized, which leads to serious pathological changes, to cardiovascular and oncological diseases, as well as to premature aging. The harmful effect on the body of "free radicals" may be reduced by the systematic use of some drugs, biologically active substances that have high antioxidant activity. So, the problem of antioxidant search is perspective and relevant.

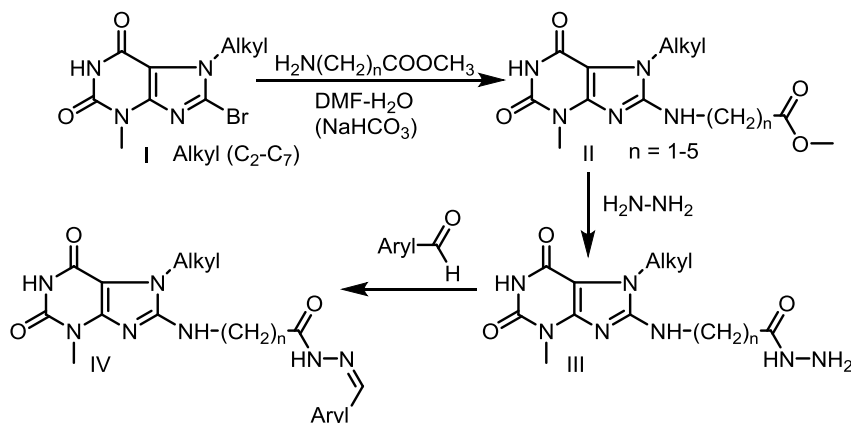
The aim of this work is to develop simple laboratory methods for the synthesis of previously unknown in the literature derivatives of 7-alkyl-3-

methylxanthinyl-8-aminoalkanoic acids, and to study their spectral characteristics and antioxidant activity.

As shown in the scheme, a number of esters of xanthinyl-8-aminoalkanoic acids (II) were obtained by reaction of 7-alkyl-8-bromo-3-methylxanthines (I) with methyl esters of aminoalkanoic acids, and corresponding hydrazides (III) and benzylidene hydrazides (IV) were synthesized on their basis.

The structure of synthesized compounds is confirmed by the data of elemental analysis, IR- and ^1H NMR-spectroscopy. Based on the data of ^1H NMR, benzylidenehydrazides IV were determined to form as a mixture of E- and Z- isomers in 2:1 ratio, respectively.

Scheme



Using computer programs, quantum-chemical indices were calculated which showed that the synthesized compounds have sufficient permeability in living systems, and therefore conducting experiments in vitro and in vivo would be appropriate. Acute toxicity was studied using the Kerber method. According to the indicators of acute toxicity, the synthesized compounds are classified as toxic class IV.

Antioxidant activity was studied in vitro on the non-enzyme initiation model of free radical Fe²⁺ oxidation and using the DPPH-test by Al-Omar et al. Mexidol, and ascorbic acid were used as benchmarks for comparison. It has been established that the majority of synthesized compounds in

terms of antioxidant activity are approaching or exceeding comparative standards.

The obtained data testify to the promise of this class of compounds as antioxidant agents. Some regularities in the row "chemical structure - biological action" are established. For final conclusions, additional research is needed. Research in this area continue

Sarafinyuk L.A., Khavtur V.O., Fedoniuk L.Ya.,
Khapitska O.P., Sarafinyuk P.V.

**CONNECTIONS OF RHEOVASOGRAPHY PARAMETERS OF
THE THIGH WITH CONSTITUTIONAL INDICATORS IN
VOLLEYBALL PLAYERS**

¹*National Pirogov Memorial Medical University, Vinnytsya, Ukraine;*

²*SHEI "I. Ya. Horbachevsky Ternopil State Medical University of the
Ministry of Health of Ukraine", Ternopil, Ukraine;* ³*Vinnitsia State
Mykhailo Kotsyubynskyi Pedagogical University, Vinnitsa, Ukraine*

To date, numerical studies are devoted to the study of the relationship between the constitutional features of the human body and the functional parameters of organs and systems of the organism (Lemkeat al., 2013). Particular attention is paid to the study of the cardiovascular system, including changes in the parameters of peripheral hemodynamics, depending on the anthropometric dimensions (Hunas at al., 2017). However, there are no data on the relationship between the parameters of peripheral hemodynamics of the body and the somatic characteristics of highly skilled athletes engaged in volleyball.

The purpose of our study was to establish the relationship between the rheovasography parameters of the thigh with constitutional indicators in volleyball players.

We surveyed 129 girls, who are engaged in volleyball, aged from 16 to 20 years inclusive. Sports experience in all volleyball players was more than 3 years. The rheographic parameters were determined using a computer diagnostic complex, the analysis of the quantitative parameters of the rheovasogram was carried out in time, amplitude and integral (derived from amplitude and time) indicators by the method of Ronkin

M.A. and IvanovL.B. (1997). Anthropometric investigation was carried out using Bunak technique (1941), and somatotypological research based on the estimated modification of the Heath-Carter method (1990). Determination of the composition of the body mass was carried out by the Mateiko method (1992).

It was established that at volleyball players the time indices of the rheovasogram of the thigh with the parameters of the external structure of the body had numerical direct correlations, and the most numerous connections were the time of slow blood flow (with total and longitudinal body dimensions, girths and width of the epiphyses of the thigh and shin, chest size, muscle and bone mass of the body) and the time of the ascending part of the rheogram (mainly with longitudinal and cordial body dimensions, muscle and fat mass of the body). The amplitude parameters of the rheogram of the thigh had only reliable ties with individual parameters from different groups of anthropometric dimensions. Integral indices also had a small number of reliable connections, except for the average slow blood flow rate, which was inversely proportional to most of the parameters of the external structure of the body, except for the ectomorphic component of the somatotype, with which there were direct correlations.

Thus, an increase in the mass and area of the body surface, the circumference of the body, the diameter of the chest, the fat folds on the lower limb, the endomorphic component of the somatotype, the muscle and fat mass of the body leads to a pronounced slowing of the blood flow of the arterial link of the circulatory channel of the thigh in the girls, who are engaged in volleyball.

The obtained results concerning the interrelations of the rheographic parameters of the thigh with the constitutional characteristics of the body in volleyball players make it possible to apply a method of stepwise regression analysis for the development of individual indices of peripheral hemodynamics, depending on the peculiarities of the body structure.

Semchenko V.A., Voronych V.O.

DETERMINATION OF ISCHEMIC RISK IN PATIENTS WITH MYOCARDIAL INFARCTION

SHEE „Ivano-Frankivsk National Medical University”, Department of Internal Medicine №2 and Nursing, Ivano-Frankivsk

The approach to the management of patients with myocardial infarction (MI) is largely dependent on the risk of adverse outcome associated with myocardial ischemia (death /nonfatal myocardial infarction), which has received the title of ischemic risk in the international literature. Assessment of the stratification of the risk of developing an unfavorable course of MI is a multifaceted problem. Nowadays such risk prediction scales as TIMI, PAMI, CADILLAC, GRACE, PURSUIT, STIMUL, SYNTAX are used for assessment, which are developed on base of clinical studies. The most powerful in its prognostic value and easy to use is the GRACE (Global Registry of Acute Coronary Events) scale.

To determine the ischemic risks of nosocomial and six-month survival of patients with MI with elevation of the ST segment depending on the treatment method.

The study involved 70 patients with myocardial infarction with elevation segment ST. The age of the patients varied from 40 to 75 years, the average age was 61.16 ± 5.79 years. Among the surveyed, men dominated 47 (67.1 %).

The patients were randomized into three groups. Group 1 included 35 people who underwent primary percutaneous coronarography intervention (PCI) with stenting of a heart attack-dependent coronary artery (HADCA). The second group included 23 patients undergoing pharmacovigilance therapy (TLT with further PCI HADCA). The third group included 12 persons, who underwent only medical treatment without PCI. Average timing of PCI were $9.5 \pm 3,4$ hours from the beginning of the MI (6 to 12 hours).

The assessment of the risk of nosocomial and six-month survival of patients (GRACE scale) was calculated using a special program calculator for stationary computers or PCs - «Macromedia Flash Player 7». The total number of points was determined and the total mortality risk was estimated during hospital stay (D), risk after 6 months (D_6), the risk of death with the possibility of a reinfarction during hospital stay (DM) and after 6 months (DM_6).

In the group of patients, who performed the primary PCI HADCA the total mortality risk, reinfarction or recurrent infarction during the hospital stay (D) in patients with MI after the performed PCI, the HADCA was (3.43 ± 0.12) %, after 6 months (D_6) - (6.46 ± 0.34) %; The DM was (6.97 ± 0.45) %, and the death or recurrent MI within 6 months (DM_6) - (24.95 ± 1.18) %. Angiographic success was achieved in 98% of patients and was accompanied by positive clinical effects and ST segment resolution up to 50% in the first hours after PCI.

In 23 (28.75%) patients, PCI was primary and was performed after unsuccessful TLT. The total mortality risk, re-infarction or recurrent infarction during hospital stay (D) was (4.68 ± 1.7) %, after 6 months (D_6) - (12.2 ± 1.35) %; the risk of death with the possibility of a reinfarction during the stay in the hospital (DM) was (21.1 ± 1.03) %, and death or recurrent MI within 6 months (DM_6) - (34.25 ± 1.70) %.

To the group of patients who received only medical therapy included older persons with contraindications to PCI and TLT. The endpoints in these patients were: D - (9.76 ± 0.55) %, D_6 - (15.63 ± 0.89) %, DM - (26.85 ± 1.54) %, and DM_6 - (26.65 ± 1.83) %.

Consequently, the GRACE scale is very easy to use, which allows it to be used already at the stage of the intensive care department during the hospitalization of the patient and to provide adequate medical aid due to the risk. It has been established that the risk of death by GRACE scale in patients with MI after revascularization by stenting HADCA is lower than in patients without reperfusion therapy.

Shcherbyna I.M., Naguta L.O., Plakhotna I.Yu.

**CRYOGENIC FACTORS IN VIOLATION OF MENSTRUAL
FUNCTION IN WOMEN OF REPRODUCTIVE AGE**

*Department of obstetrics and gynecology№1, Kharkiv National Medical
University, Kharkiv*

The frequency of gynecological diseases, namely, abnormal uterine bleeding (AUB) reaches 25-30% of the total pathology.

In recent years, doctors are increasingly turning to non-invasive and non-hormonal treatments. Symptomatic hemostatic therapy, uterotonics, physiotherapy, vitamin therapy are not sufficiently effective. Cryosurgery, chemical degradation by the method of Grammatikate or ablation of the endometrium with the help of hysteroscopy is sufficiently traumatic methods and lead to loss of reproductive function.

All this prompts the search for the latest treatments, combining traditional treatment with physiotherapy.

The solution to this problem is possible due to the rapid development of cryotechnologies. The cryogenic effect increases the nonspecific and immunological reactivity of the organism, improves the metabolism of the body, the function of the central nervous system, restores the hormonal balance, carries a generally stimulating effect on the body as a whole. All of the foregoing determines the feasibility of finding modern methods of treatment for AUB to eliminate this pathology in women of reproductive age.

The aims. To investigate our aim, we have identified the effectiveness of cryotherapy.

Materials and methods. We conducted a comparative analysis of the results of treatment of AUB: 14 women included in group 1, used hormonal treatment, and the second group included – 13 patients who used a complex therapy including cryotechnology. The 3rd group consisted of 10 healthy women. All patients had complaints of weakness, fatigue and menstrual irregularities.

In order to diagnose, we took into account all women's complaints, clinical and laboratory methods of research, hormones - the determination of hormones in serum of blood (follicostimulating (FSH), luteinizing (LH) hormones, estradiol, progesterone), histological and ultrasound examination of small pelvic organs.

Results and discussion. Normalization of menstrual function was determined in 11 (78%) women in group 1 compared with women in the 2nd group - 12 patients (92%) and 3rd group 9 healthy women (90%) respectively. In women of the first group there was a need to discontinue hormonal therapy, as a result of deterioration of the general well-being of patients. Clinical efficacy of cryofactors in the treatment of women with AUB is confirmed by the results of hormonal, clinical laboratory test, histological and ultrasound studies.

At the same time, in all patients of groups 2 and 3, general condition improved, menstrual bleeding ceased, menstrual period decreased, and the normalization of hormone levels: FSH – $4,9 \pm 0,2$ MU/l, LH – $8,3 \pm 1,2$ MU/l, estradiol – $110,2 \pm 7,5$ pg/ml, progesterone – $13,3 \pm 1,3$ ng/ml. All patients who received cryotherapy 6 months after the end of therapy had an ultrasound examination, in which the pathology of the endometrium was not defined.

The data received, the absence of relapse and positive dynamics, indicate the effectiveness of the treatment.

Shcherbyna M.O., Lipko O.P., Kurichova N.Yu.

**PATHOGENETIC ESSENCE OF CHRONIC INFLAMMATION
IN UTERINE BLEEDING IN WOMEN IN THE
PERIMENOPAUSAL PERIOD**

*Department of obstetrics and gynecology №1, Kharkiv National Medical
University, Kharkiv*

In women of the perimenopausal age, the most common gynecological pathology is uterine bleeding and bloody discharge from the genital tract, which rank first among the causes of hospitalization. According to the traditional tradition, uterine bleeding in perimenopausal patients is diagnosed as climacteric. The pathogenetic nature of climacteric bleeding consists of age-related involutinal changes in the hypothalamic-pituitary-ovarian system, accompanied by an imbalance of gonadotropic hormones. As a result of violations of cyclic allocation of gonadotropins, develops relative hyperterigenicity against the background of absolute hypoprogesteroneemia.

The purpose of this study was to evaluate the frequency of chronic inflammatory diseases of the internal genital organs in perimenopausal patients who have uterine bleeding.

Materials and methods. The analysis of results of histological examination of scrapings (aspirates) of the mucous membrane of the cervical canal and endometrium, operating material taken in 64 patients of the perimenopausal age has been carried out. The perimenopausal age in the examined patients ranged from 47 to 53 years. Endometrial and mucosal secretions of the cervical canal were obtained with a separate scaphoid in 53 patients. Extirpation (amputation) of the uterus with appendages was performed in 11 patients. Endometrial and mucosal secretions of the cervical canal were reported with a clinical diagnosis of dysfunctional uterine bleeding and climacteric bleeding.

Results and discussion. According to the results of the histological study, the material was divided into 2 main groups: 1st group (n=35) – non-inflammatory pathology of the body and cervix (hyperplastic processes including endometrial polyps, hypoplastic endometrium, polyp of the cervical canal, uterine myoma, malignant tumors of the cervix and body of the uterus, ovaries); group 2 (n=29) – chronic inflammatory diseases of the internal genital organs. Non-inflammatory diseases of the body and cervix are often associated with a chronic inflammatory process in one of the internal genital organs and/or more. The next cause of uterine bleeding and bloody secretions from the genital tract in women of the perimenopausal age were chronic inflammatory diseases of one, two sections of the genital tract and more. Thus, inflammatory diseases of the internal genital organs, mainly chronic endometritis, in $22,6\pm 1,4\%$ of the observations led to so-called climacteric bleeding in patients with perimenopausal age. In general, chronic inflammatory diseases of the internal genital organs were detected in 53 patients. It should be noted unequal distribution between isolated and associated with non-inflammatory pathology forms of chronic inflammatory diseases.

At the heart of uterine bleeding and bloody secretions from the genital tract in the period of perimenopause, in the vast majority of cases, is associated with the form of chronic endocervitis and endometritis associated with non-inflammatory pathology of the cervix and the uterus body.

Shcherbyna M.O., Skorbach O.I., Skorbach Yu.I.

***NEW APPROACHES TO THE CORRECTION OF CLINICAL
AND METABOLIC DISORDERS IN WOMEN AFTER
HYSTERECTOMY**

*Department of obstetrics and gynecology№1, Kharkiv National Medical
University, Regional Center of Clinical Medicine, Kharkiv*

In recent years, among the radical operations on the internal genital organs, the most common in women of reproductive age is hysterectomy with or without removal of appendages. There are studies that emphasize the fact that surgical removal of the uterus, even with the preservation of ovarian tissue, in 60-85% of women is accompanied by the emergence of neuro-vegetative and psychoemotional disorders, changes in lipid and protein metabolism; promotes growth of cardiovascular diseases, in particular, arterial hypertension.

The aim of this study was to develop new approaches to the correction of hormonal and metabolic disorders in women after hysterectomy.

Materials and methods. The study included 40 women of reproductive age. All patients had a hysterectomy with preservation of both ovaries under general or spinal anesthesia. Hysterectomy with laparotomic access was performed in 90% of patients, and 10% – by laparoscopic. I group consisted of 20 women who received complex therapy, which included, in addition to traditional treatment (hormone replacement therapy (HRT)), the use of an immunomodulator, a vasodilator and sedative. The II group consisted of 20 women who received traditional treatment (HRT).

Research hormonal in serum was performed by ELISA using kits manufacturing company "Alkor Bio" (St. Petersburg, Russia).

Studies of lipid metabolism were determined by enzymatic colorimetric method in the blood serum using test systems from Roche Diagnostics (Switzerland) on an automatic biochemical analyzer Cobas 6000 (501 module). The concentration of cholesterol of low density lipoproteins was consistently calculated by the formula W.T. Friedewald (1972).

Positive clinical effect in women of I and II groups against the background of traditional and combined therapy was observed in 3-4

weeks from the beginning of treatment and correlated with positive dynamics in hormonal parameters.

In the study of the hormonal status in women after hysterectomy on the background of traditional and complex therapy, we found such changes. So, in II group, relapses were observed in 30% of women who needed additional therapy. Relapses occurred due to the preservation of hormonal imbalance (hypoestrogenemia and progesterone reduction) after the abolition of HRT. In women of I group, who received complex therapy, recurrence was not observed.

In the study of the lipid spectrum under the influence of the complex treatment performed in women of I group, there was a more rapid trend towards normalization.

In the course of the statistical analysis, it was found that the use of combined treatment in women after 6 months of hysterectomy results in significant atherogenic changes in the lipidogram: reduction in the concentration of triglycerides, total cholesterol, low density lipoprotein, and has a partially anti-atherogenic effect, which is to stabilize the concentration of high-density lipoprotein and an atherogenic index ($p < 0,05$). In women who received traditional treatment after 6 months after the operation, indicators of lipidogram only tended to normalize lipid metabolism.

Thus, the complex therapy developed by us allows us to improve the effectiveness of treatment by restoring hormonal and metabolic processes in women after hysterectomy, resulting in a stable positive clinical effect, in contrast to traditional therapy.

Shvets V.I., Shvets N.V.

THE ROLE OF THE ADIKOPINS WITH DESEASES SUCH AS OBESITY,ARTERIAL HYPERTENSION, OSTEOARTHRITIS.

Higher State Educational Establishment of Ukraine

«Bukovinian State Medical University» (Chernivtsi City, Ukraine)

Department of Anatomy, Topographic Anatomy and Operative Surgery

Obesity is increasing in the Western society, and obesity-linked complications are under intense scrutiny. Among these, not only metabolic disorders, such as diabetes mellitus and dyslipidemia, but also cardiovascular disorders, such as hypertension and ischemic heart

diseases, have been shown to be associated with obesity. More recently, also chronic diseases in which inflammation plays a role such as osteoarthritis, rheumatoid arthritis, inflammatory bowel disease, chronic obstructive pulmonary disease, and asthma have been associated with obesity.

Arterial hypertension, Osteoarthritis and their coincidence, as proven, may have benefit from omega-3-polyunsaturated acids implication. Adipokines (leptin and adiponectin) levels are investigated and compared depending on body mass index in patients with mentioned pathology; dynamics of values investigated under influence of omega-3-polyunsaturated acids implication. Established, that omega-3 fatty acid supplementation has potential of restoring of natural balance of adipokines (leptin, adiponectin) and mild lipid-lowering action in obese patients with arterial hypertension, osteoarthritis and their combination, so, seems to be useful in therapeutic patterns for mentioned diseases. Exact mechanisms, dosage and longer duration of therapy may be promising subject for further investigation.

Diseases or pathologies that are discussed as those which may have benefit from omega-3-polyunsaturated acids implication include (but are not limited by) diabetes and metabolic syndrome, nephropathy, ischemia-reperfusion injury, cardiovascular diseases and arterial hypertension in partial, pulmonary inflammation, and chronic inflammatory disorders. With the rising epidemic of obesity, more efficacious therapeutic strategies are needed to address the complex pathophysiological events that lead to metabolic syndrome.

The adipose tissue consists of adipocytes and the stromal vascular fraction, in which a variety of immune cells can be found. Among these, macrophages and T-cells are the most abundant. Expansion of the adipose tissue is accompanied by an increased infiltration of immune cells with a pro-inflammatory phenotype. The cross-talk between the infiltrating cells and the tissue-resident adipocytes leads to secretion of adipokines, cytokines, chemokines, and lipids with a predominant pro-inflammatory character. Moreover, the levels of various adipokines and cytokines are altered in obese individuals compared to lean ones (e.g., leptin, adiponectin, IL-6). So it seems so that one of therapeutic strategies must

be directed to normalization of not clinical values only but for correction of mentioned molecular interplay.

Omega-3-polyunsaturated fatty acids are able to inhibit partly a number of aspects of inflammation including leucocyte chemotaxis, adhesion molecule expression and leucocyte- endothelial adhesive interactions, production of eicosanoids like prostaglandins and leukotrienes from the n- 6 fatty acid arachidonic acid, production of inflammatory cytokines and T cell reactivity. Mechanisms underlying the anti- inflammatory actions of n- 3 fatty acids include altered cell membrane phospholipid fatty acid composition, disruption of lipid rafts, inhibition of activation of the pro- inflammatory transcription factor nuclear factor kappa B so reducing expression of inflammatory genes, activation of the anti- inflammatory transcription factor NR1C3 (i.e. peroxisome proliferator activated receptor γ) and binding to the G protein coupled receptor GPR120. These mechanisms are interlinked.

Omega-3 fatty acid supplementation has potential of restoring of natural balance of adipokines (leptin, adiponectin) and mild lipid-lowering action in obese patients with arterial hypertension, osteoarthritis and their combination, so, seems to be useful in therapeutic patterns for mentioned diseases. Exact mechanisms, dosage and longer duration of therapy may be promising subject for further investigation.

Stoliar D.B.

**FEATURES OF THE STRUCTURE OF THE HUMAN
TEMPOROMANDIBULAR JOINT IN THE THIRD TRIMESTER
OF THE INTRAUTERINE GROWTH**

Higher State Educational Establishment of Ukraine

«Bukovinian State Medical University» (Chernivtsi City, Ukraine)

Department of Histology, Cytology and Embryology

Despite the progress and intensive development of dental technology, there are still many unexplained issues regarding the structure of the dentition elements. One of its important structures is the temporomandibular joint (TMJ).

The goal of the research was to study and to determine anatomical peculiarities of the TMJ in the third trimester of the intrauterine development. The study was carried out on 12 specimens sized from

301,0-450,0 mm of crown-rump length. The following methods were used in the course of the study: morphometry, craniometry, macro- and microdissection, computed tomography.

Analysis of the results of our own studies demonstrates that in the third trimester of the intrauterine development topographic an atomical interrelations of the temporomandibular joint develop rather dynamically and it occur sinclose correlation with adjacent an atomical structures. The temporomandibular joint is characterized by a flat articular fossa and appearance of the articular tubercle at the 7-8th month of the intrauterine development in the form of prominence on the inferior surface of its condylar process base. The majority of cranio- and morphometric parameters increase evenly. Identification of correlation bonds between cranio- and morphometric parameters of fetuses and neonates with the parameters of the temporomandibular joint depending on sex is considered to be reasonable. Further study of the temporomandibular joint will promote verification of the findings obtained by means of USD, CT, MRI, and will form the basis for detection of critical periods in the development of the facial part of the human cranium in fetuses.

Guzik O.V., Navarchuk N.M., Hresko A.S., Sribnyak A.Z.

MORPHOLOGICAL PECULIARITIES OF THE JUXTAORAL ORGAN OF CHIEVITZ

*Department of Anatomy, Topographical anatomy and Operative surgery
Higher State Educational Establishment of Ukraine "Bukovinian state
medical university", Chernivtsi*

The the juxtaoral organ of Chievitz (JOC) is a vestigial anatomical structure which is not usually described in lectures and classic texts of general histology and oral histology. The literature contains cases in which JOC was identified in specimens removed because of a malignancy and the correct recognition of this structure potentially avoids unnecessary treatment.

Aim: to ascertain the morphological peculiarities of JOC.

Materials and methods: the study and analysis of materials of domestic and foreign literature.

Results. In 1885, the Danish histologist Chievitz had described a rudimentary structure developing and disappearing during the embryonal

period, loping and disappearing during the embryonal period, but Zenker reported persistence of the neuroepithelial organ throughout life without involution, and termed it the "juxtaoral organ". The JOC, composed of both epithelial parenchyma and supporting mesenchyme, first appears in embryos measuring 0.75 to 1.2 cm in length. This is a small fusiform structure, interposed between the fascia buccotemporalis and pterygoid muscles, that is innervated by 2 to 4 branches of the buccal nerve. The parenchyma is represented by a long, continuous mass of epithelial cells, which appear as multilobulated, circumscribed nests. These epithelial clusters, resting on a basement membrane, are present both around (perineural space) and within (endoneural space) nerves. The nerve fibers showed strong positivity for S-100, CD56 and synaptophysin. Immunohistochemical studies with GFAP and NSE have reported contradictory results. The function of the JOC is controversial.

The JOC is a structure that can frequently be found in the normal anatomy of an individual. Its function has not been clarified, which is why it is presumed to be a dispensable structure, although knowledge of it is important to avoid the erroneous diagnosis of an invasive process from a malignant oral mucosa lesion.

Marchuk O., Pasichnyk A., Marchuk O.

CAUSES OF TRANSIENT SYNOVITIS IN CHILDREN

*Bukovinian State Medical University, Department of Anatomy,
Topographic Anatomy and Operative Surgery, Chernivtsi*

The research is relevant because of the fact that transient synovitis is often found as a short-term non-specific inflammation of the synovial membrane of the hip, and less commonly in knee joints in children, more often in boys. The development of the process is often associated with a small trauma or a disease with a low-grade temperature, such as bacterial diseases of the respiratory tract and oral cavity (tonsillitis, pharyngitis); with long walking.

Synovitis is an inflammation of the synovial membrane lining the joint from the inside. The disease is accompanied with excess fluid leakage and subsequent inflammatory changes in the joint. The peculiarity of this ailment is that at an early stage the child may have no complaints, and when they arise, the treatment may be complicated and difficulties

arise in differential diagnostics with other diseases of the musculoskeletal system in children. Transient synovitis of the joints in children occur quite often, but the pathogenesis of this disease is practically not studied. Basically, synovitis develops in children from one and a half years to the period of puberty. The similarity of clinical manifestations of TS with other diseases of joints in children requires a thorough investigation of the causes, as well as the determination of the main differential diagnostic criteria that allow to diagnose the disease in time correctly and begin adequate treatment.

The purpose of our research was to establish a list of the main causes of the TS in children of Chernivtsi region.

The research was conducted on the base of 72 histories of disease for 12 months at the City Children's Clinical Hospital in Chernivtsi. We used world literature, the mass media of Bukovina, statistics method of data processing.

Our research has shown that causes of the disease may be the following conditions:

Excessive joint loading due to children high activity and lack of movements precise coordination.

Infections (acute respiratory infections, flu, parainfluenza and their complications - bronchitis, tonsillitis, etc.). Pathogenic microorganisms entering the body can cause pathological changes in the synovial membranes of the joints, which carry the greatest load during physical activity.

Diseases of the internal organs (especially the gastrointestinal tract) and the immunity specialities, individual anatomical and physiological features.

According to the results of our observation, the most common cause of transient synovitis is respiratory viral infectious diseases. During the year, most children suffer from seasonal acute respiratory infections, of which about 4-5% have complications in the form of TS. Of the 72 patients we cooperated with, 42 had acute respiratory infections, 22 children had pathology of the gastrointestinal tract (gastroduodenitis, gum dyskinesia, etc.), with TS 5 patients.

Influence of infectious diseases on the occurrence of transient synovitis, in our opinion, is in the following information: when the virus

enters the child's body, the substances causing inflammatory reaction - the immune response of the body to the antigen - are released into the bloodstream. With blood flow, these inflammatory mediators fall into the synovial fluid of the joint, causing in some cases its inflammation, which manifests itself in joint pain. In the synovial membranes of the joint may be the pathogen itself infectious diseases, causing its pathological changes. The difference between synovial bags in sick children and those who after flu did not have TS, little studied by scientists at the moment; no anatomical differences were found. Probably, everything depends on the immunological features of synovial fluid and synovial membranes.

To sum up, according to our research, the main causes of TS in children are respiratory viral infections, overload and minor injuries to the joints, diseases of the internal organs. The nature of the influence of infectious diseases and their complications on the having TS is in the next information: when an infectious pathogen is infected, an immune response arises, the inflammatory mediators, as well as the pathogen itself, can penetrate into the cavity of the joint, which can be accompanied by the development of transient synovitis with certain unfavorable factors.

Aryak Ipsit, Olga Kushniryk

FREQUENCY OF BOMBAY PHENOMENON IN THE WORLD

Higher State Educational Establishment of Ukraine

“Bukovinian State Medical University”, Chernivtsi, Ukraine

Bombay phenomenon is used to be associated only with Indian population, but cases of this phenomenon were recorded in the world too. It is estimated that only 4 per million people have it in the world, although the incidence of this blood type is slightly higher in Mumbai, where 1 in every 10.000 people are diagnosed with it. According to the mentioned above, an aim of our survey was to evaluate the share of this phenomenon cases in the world.

Bombay phenomenon is a rare recessive trait at a locus that ordinarily manufactures H substance, the precursor from which the A and B phenotypes are elaborated; the mutant causes failure to produce H substance and no matter what the genotype at the AB0 locus, the phenotype is O. The Bombay phenomenon is epistatic to the AB0

locus. The specificity of the H antigen is determined by the sequence of oligosaccharides. More specifically, the minimum requirement for H antigenicity is the terminal disaccharide fucose-galactose, where the fucose has an alpha-(1-2)- linkage. H deficiency is rare: it is found in 1 of 8.000 in Taiwan, 1 of 10.000 in India, and 1 per million in Europe. It is quite rare in Caucasian with an incidence of 1 in 250.000. In general, people carrying Bombay blood do not differ from the usual ones. However, problems arise when a transfusion is required (a serious operation, an accident or a disease of the blood system). Due to the peculiar antigenic composition of these people, they can not be transfused with other blood, except bombs. Especially often such errors occur in extreme situations, when there is no time to thoroughly study the analysis of red blood cells of the patient, because the patient needs only Bombay blood, necessarily with the same rhesus as his.

Thus, people having Bombay phenotype are mostly confined to the Southeast Asia. One of the hypothesis of Bombay phenomenon appearance is mainly related to the extensive inbreeding within the same lineage or close-community marriages, such that the “blood type” or the gene pool is significantly restricted.

Haba M. Y., Pavliv Kh. I., Masna Z. Z.

MORPHOFUNCTIONAL PECULIARITIES OF GASTRIC MUCOSA UNDER THE OPIOID INFLUENCE.

Danylo Halytsky Lviv national medical university

Department of the Operative Surgery and Topographic Anatomy

Lviv

It is known that opioids have cytoprotective effect on gastric mucosa during the influence of different ulcerogenous factors. The aim of the research was to investigate structural and morphological changes of gastric mucosa under the dalargin influence, during the noradrenaline ulcerogenous impact.

Materials and methods. The experiment was performed on 30 sexually mature male rats with a body weight of 180-200 g and a 3.5-

month old age. Experimental animals were kept at the vivarium of the Danylo Halytsky Lviv National Medical University. Structure-hemorrhagic lesions were caused by noradrenaline injections (dose – 2.0 mg/kg). Dalargin was injected in the dose of 0.1 mg/kg. Activity of peroxidation of lipids was determined by the malonic dealdehyde level and activity of enzymes of antioxidant protection was evaluated by the contents of SOD and catalase, level of nitric oxide was measured by means of Griess reagent.

Changes of gastric mucosa components due to combined action of dalargin and noradrenaline as compared to those resulting from the solitary action of noradrenaline were as follows:

- increased number of preserved epithelial cells, absence of necrotized areas, accumulation of mucous granules in the epithelial cells;

- increased content of low-differentiated cells in the cervical part of the gland, probably, at the account of stimulating effect of dalargin upon regenerative process, solitary erythrocytes and leukocytes found in hemocapillaries;

- maintained structure of the secretory cells;

- nonexpressed intracellular secretory canaliculus in the parietal cells;

- basic cells contained granules of protein secretion;

- connective tissue remained intact and contained great numbers of eosinophilic granulocytes.

At that, content of malonic dealdehyde decreased by 54% ($p < 0.05$) and concentration of natrium oxide displayed a slight increase, associated with enhanced activity of enzymes of antioxidant protection, primary of catalase (by 41%, $p < 0.05$).

Thus, dalargin has manifested a expressed cytoprotectonal effect associated with preserved integrity of gastric mucosa components, redused lipoperoxidation, and enhanced activity of catalase.

Herasymiuk M.I.

THE USE OF DATA OF SOME MODERN LABORATORY EXAMINATION METHODS TO UPGRADE INDICATIONS FOR TUNSELECTOMY

SHEE "I. Horbachevsky Ternopil State Medical University of Ministry of healthcare of Ukraine", Department of Otorhinolaryngology, Ophthalmology and Neurosurgery, Ternopil

At present, thanks to the successes in solving the theoretical foundations of the immunophysiology of the tonsils, the tonsillar problem in its clinical aspect has shifted towards the sparing attitude to the lymphoepithelial structures of the oro- and nasopharynx. Though, tonsillectomy remains one of the techniques that continue to be performed by otolaryngologists. Therefore, the problem of choosing an optimal method of treatment in chronic tonsillitis (ChT) remains relevant.

The purpose of this work was to identify features of changes in the subpopulation composition of blood and tonsil tissue lymphocytes in comparison with apoptosis and necrosis and separate data of the cytokine spectrum as additional criteria for diagnosis, prognosis and choice of treatment method for patients with chronic tonsillitis.

The survey was conducted in 36 patients with chronic tonsillitis, 20 cases of which were used conservative treatment and 16 patients were surgically treated. The control group consisted of 15 practically healthy persons without signs of ENT pathology. Determination of state of the subpopulative composition, as well as the state of apoptosis and blood lymphocytic necrosis and their correlation AN/PI (based on markers of apoptosis - "ANNEXIN V FITC" and necrosis PI - propidium iodide) were performed on a flow cytometric flocculator "Becmen Culter Epix XL" (USA). In this case, the dynamics of changes in the relative and absolute number of different subpopulations of lymphocytes (from CD3 +, CD4 +, CD8 +, CD16 + and CD19 + receptors) were determined. The level of cytokines (gamma interferon - IFN γ and interleukin-4 - IL-4) of lymphocytes was determined on the immuno-enzyme analyzer STAT FAX 303/PLUS, and also the correlation of their concentrations was calculated. Each of the examined groups of patients was divided into 2 subgroups: with a decrease in the ratio of IFN- γ /IL-4 in the treatment process and with its growth.

The established dynamics of quantitative changes in various subpopulations of lymphocytes, indicates significant changes in the immune system under conditions of chronic tonsillitis. In particular, this is confirmed by the low level of CD3+ and CD4+ lymphocytes in the peripheral blood. Such a decrease was more pronounced in patients who had indications for surgical treatment. This may be a manifestation of the intensity of the pathological process. Thus, in patients who underwent tonsillectomy, the relative level of CD3+, CD4+ and CD8+ -lymphocytes before the operation was lower respectively on 30.96%, 16.29% and 1.29% than in the control. In patients who were prescribed the conservative treatment, this difference was 27.07%, 10.90% and 0.85%. A similar dynamics was observed when calculating absolute indices of CD3+ and CD4+ -lymphocytes. At the same time, the absolute level of CD8+ lymphocytes remained virtually unchanged. Regarding CD16+ lymphocytes, although their relative level before treatment was lower than the control in both studied groups, but the absolute number did not differ significantly from that of the control group. At the same time, the level of CD19+ -lymphocytes tended to increase by its absolute value only in patients who were prescribed the further conservative therapy. Both surgical and conservative treatment contributed to the partial restoration of the absolute and relative number of studied subpopulations of lymphocytes.

In parallel with changes in the subpopulation composition, we have noted changes in the level of apoptosis and necrosis of blood lymphocytes and their correlation. Moreover, changes in the level of apoptosis were more pronounced, while the level of necrosis was significantly less fluctuating. In particular, the level of apoptosis in patients before the operation was significantly higher by 81.8% than the control level, while in patients with conservative treatment, this exceeded 53.6% ($P < 0.05$), the AN/PI ratio in these groups of patients exceeded the baseline data by 78.0% and 21.7% respectively. Thus in patients who were indicated for the surgical intervention, this ratio significantly exceeded that recorded in patients who were prescribed the conservative treatment. After the treatment, the level of correlation in both groups decreased and became close to the baseline data, although the absolute level of apoptosis

continued to be reliably 20.1% and 35.3% higher than control. So its more intense reduction occurred again after the surgical removal of tonsils.

The prevalence of the results with a decrease in the ratio of IFN- γ /IL-4 in patients after surgical treatment, and prevalence of the results with its increase in patients after conservative treatment, also suggests that an increase in the ratio of IFN- γ /IL-4 is a favorable prognostic sign for conservative treatment, and its decrease may indicate a high level of allergy, which in the future may lead to the transition of a simple form of ChT into a toxic-allergic form with the appropriate correction of tactics of further treatment.

Thus, our research suggests that the use of such laboratory parameters as the state of the subpopulative composition of lymphocytes, their apoptosis and necrosis, as well as the comparison of these indicators with the level and dynamics of cytokines (in particular gamma-interferon-IFN γ and interleukin-4 - IL-4) can be additional informative enough criteria when choosing a treatment tactics for patients with chronic tonsillitis.

Sorohan M.M., Pleguca O., Popova M.

FEATURES OF CHANGES IN A BONE TISSUE

Higher State Educational Establishment of Ukraine "Bukovinian State Medical University", Chernivtsi (Ukraine) Department of Anatomy, Topographic Anatomy and Operative Surgery, Chernivtsi

Some violations appears as affect of inflammatory process In a bone. The most common change in a structure of jawbone tissue is atrophy of the alveolar appendix. Often it appears during early teeth loss and in a time of being without teeth in the mouth. Herewith the pressure on the alveolus greatly increases in the area of missing tooth, that is why beginning dystrophic processes.

A bone tissue is consists of cell and specific compact substance. These compact substance is made of hydroxyapatite, which means a combination of phosphoric acid and some calcium salts.

The bone including collagen and own bone cells, which divided into two types: osteoblasts and osteoclasts. Osteoblasts are specific islets from cells, which promotes collagen synthesis. Herewith trabeculae are formed, which made of collagen and salts of calcium. Osteoclasts are the opposite. They just help to quickly destroy the bone. In that situation repair will be

complicated. In their cytoplasm are many lysosomes, which produce specific proteolytic enzymes, which influence on the process of Collagen fiber collapse on the separate amino acids.

Throughout the life processes are continuous and are controlled by cells. The bone always destroys and restores during the life, but it is happening imperceptibly. And bone tissue atrophy is most likely to develop in adulthood, because repair of tissue happens slower, than osteoclasts formation.

The main reasons of jaw atrophy: early tooth loss. Even when one tooth is missing, all the other teeth begin to move in a way to the defect. Some pathologies are of a systemic nature. Usually, people get sick on that, when they have problems with thyroid and ovarian functions. Destruction of the alveolus of the teeth begins, because number of hydroxyapatite is decreases. This contributes to the reduction of strength of bone teeth tissue, which is in a place of defect. Herewith the repair normal structure of the bone is quite possible.

Age involution of the jaws. If there is no tooth in the oral cavity for a long time, then its bone plate gradually wears out. As a result blood supply becomes slower, that is why bone tissue can crumble. As a result – bone jaw tissue can't be restored.

Guzik O.V., Navarchuk N.M., Shishela M.S., Shkvarkovska A.I.

**FETAL DEVELOPMENT AND MORPHOLOGICAL
PECULIARITIES OF THE FACIAL NERVE**

*Department of Anatomy, Topographical anatomy and Operative surgery
Higher State Educational Establishment of Ukraine "Bukovinian state
medical university", Chernivtsi*

The study's data contributes to the limited knowledge in the current literature on algebraic anatomy of fetal facial nerve (FN). The FN anomalies may be associated with congenital hearing loss, Turner's syndrome, Treacher-Collin's syndrome, congenital stapes fixation, congenital aural atresia, CHARGE syndrome, congenital microtia, Klinefelter syndrome, trisomy 13, Antley-Bixler Syndrome, and

DiGeorge syndrome. Materials and methods: the study and analysis of materials of domestic and foreign literature.

In a 4,2 mm embryo, the FN arises in common with the eighth cranial nerve and is attached to the metencephalon just rostral to the otic vesicle. In 18,0 mm embryos the nervus intermedius is considerably smaller than the motor root of the FN and is arranged as one or two main bundles that pass from the geniculate ganglion to the brainstem between the motor facial root and the acoustic nerve. In pre-fetuses 20,2-41,0 mm the FN becomes proportionally smaller in relation to the total cranial region and its peripheral branches gradually approach the definitive condition. Before 4 month of the fetal life, the FN is observed to lie in a narrow sulcus within the primordial otic capsule and Reichert's cartilage. Between 16 and 21 weeks multiple endochondral and intramembranous ossifications appear in the cartilaginous otic capsule. At 24 weeks, the ossification and fusion of the superior and inferior clasp. At 40 weeks, approximately 83% of the facial canal is formed and this process continues after birth. The lengths of mastoid segments in neonatal, infancy, toddler, preschool, school and adolescent groups were $5,03 \pm 0,84$, $6,25 \pm 1,40$, $8,34 \pm 1,38$, $9,70 \pm 1,34$, $10,84 \pm 1,41$ and $12,17 \pm 1,83$ mm, respectively ($P < 0.05$). The percentage of dehiscence in geniculate fossa segment was decreased significantly with age (neonatal group 85,7%, infancy group 59,4%, toddler group 39,2%, preschool group 33%, school group 30% and adolescent group 26,8 ($P < 0.05$).

Information on the fetal development and morphological peculiarities of FN may be useful for pediatric surgeons, otosurgeons and neurosurgeons.

Ostapchuk V.G., Popovich V.V.
**MODERN VIEWS CONCERNING OCCURRENCE OF
ULCEROUS DISEASE AND IMPROVEMENT OF
ANTIBACTERIAL THERAPY IN CHILDREN**

*Ph.D. Associate Professor in Pediatrics and Medical Genetics
Higher State Educational Establishment of Ukraine "Bukovinian State
Medical University", Department of Pediatrics and Medical Genetics,
Chernivtsi, Ukraine*

Diseases of the digestive organs have always been focused by doctors due to their considerable occurrence, peculiarities of the course and a high risk of early disability development. Ulcerous disease (UD) is of the most social and medical value among them, since it has taken a leading position by its rate in the structure of diseases of the gastroduodenal region. UD is evidenced to occur 2-3 times as often among urban children than among rural ones; and 7 times as frequently among schoolchildren than that of preschoolers. In spite of introduction of a powerful arsenal of anti-secretory and anti-helicobacter means into practice, as well as pharmacogenetic researches enabling to predict the effect of medicinal means for every certain patient taking into account possibilities of response of a macroorganism to the factors of aggression, strategic and tactical issues of UD therapy are not completely clarified. According to Maastricht Consensus all the patients suffering from *H. Pylori*-associated UP are administered to antimicrobial preparations, regardless of the period of the disease and the character of the course. Taking into account a wide use of anti-bacterial means, it is necessary to examine factors carefully that can serve as a reason of unsuccessful outcome of eradication. Researches of the recent years have proved that a long-term imbalance of immune response is found in children with helicobacter-associated diseases of gastro-duodenal area that is additionally complicated by immunosuppressant action of drugs indicated for eradication therapy. Our attention was attracted by a modern immunoactive medicinal means - polyoxidonium. Depending on the algorithm of treatment UD patients, 12-18-years-old, were divided into two sub-groups: the first one (30 patients) received a protocol treatment according to the order of the Ministry of Health of Ukraine № 59 dated January 29, 2013; the second group (25 individuals) received a protocol treatment in combination with

polyoxidonium in the dose 0,012 mg twice a day 30 minutes before taking meals during 10 days. The analysis of dynamics of clinical symptoms and character of endoscopic findings demonstrated that a reliably quicker disappearance of the main signs of UD was found among children from the second group. Pain and heartburn disappeared in the children of the second sub-group 3,4 days ($p<0,05$), belching – 3,3 days ($p<0,05$), nausea – 3,6 day ($p<0,05$), general weakness and headache – 2,0 day ($p<0,05$), increased fatigue – 1,7 day ($p<0,05$) earlier, than those for the children from the first sub-group. Endoscopic examination conducted on the 28th day confirmed efficiency of a comprehensive treatment of UD. Thus, in children who received polyoxidonium in a comprehensive treatment of UD, in 4 weeks the stage of white scar was diagnosed reliably more often (72,0 % against 36,7 %, $p<0,05$) and the signs of gastroduodenitis were found less frequently (36,0 % against 73,3 %, $p<0,05$), in comparison with children who received only the protocol treatment. Thus, administration of polyoxidonium in the comprehensive treatment of UD in children enables achieving more rapid and reliable reduction of clinical-paraclinical indices, obtaining quicker healing of ulcerous defect and promoting eradication of *H. pylori* with the decline of a relative risk of occurring relapses 0,56 times as much, with increase of relative benefit 0,96 times as much. The subsequent monitoring of patients is therefore conducted during a year with an additional examination in 6 months.

Shvets N.V., Shvets V.I., Tymofiychuk I.I.

**STUDY OF THE EFFECT OF ESTROGEN ON COGNITIVE
FUNCTIONS IN OLD RATS AND IN THE SETTING OF
DIABETES MELLITUS**

*Higher State Educational Establishment of Ukraine “Bukovinian State
Medical University”, Chernivtsi (Ukraine)*

Aging is a logical process characterized by a decrease in the adaptive capacity of organs and systems that, in physiological aging, have possibilities for compensation. Reducing cognitive function is a natural response of an aging brain. Limits in the cognitive field are associated with morphological changes in the structures of the brain. Age deterioration, memory anatomically depends on the hippocampus and the prefrontal cortex of the brain.

Alzheimer's disease (AD) is a neurodegenerative disease with a steady progression of memory disorders and higher cortical functions to total loss of intelligence and mental activity in general. The main histopathological signs of AD accumulation of amyloid plaques and intracellular fibrillary tangles. Neurofibrillary tangles are intracellular and consist of abnormal phosphorylated tau protein, which is a component of the microtubules.

Sex steroids also participate in the regulation of behavioral responses and provide such "nonproductive" functions as the differentiation and development of brain cells at different stages of ontogenesis. Estrogens have an effect on the plasticity of processes in the central nervous system, which provides conditions for the formation of behavioral, psychological and sexual responses. Sex hormones slow down the apoptosis of CNS cells and contribute to greater cell endurance during hypoxia, hypoglycemia, and decrease amyloid accumulation.

According to the study one of the main causes of cognitive dysfunction is the chronic hyperglycemia. Most of the indicators that determine cognitive dysfunction have been reduced in patients with diabetes mellitus 1, namely memory functions and attention.

The purpose of our work was to investigate the behavioral reactions of rats in the radial labyrinth, after ovariectomy and against the background of the development of experimental diabetes mellitus in 4-5 months old and old rats.

Animals were divided into several groups: a control group of 4-5 months which were subjected to false surgery, the study groups: 4-5 month ovariectomized, and with experimental diabetes mellitus, duration 2 months and a group of 20 months rats, which did not have estral cycles, and a group of old rats with experimental diabetes.

Ovariectomy was performed using the method of Y.M. Kabak. Experimental type 2 diabetes mellitus was reproduced by intramuscular injection of 15 mg / kg of protamine sulphate twice daily for 2 weeks. After 2 and 4 weeks after the end of the administration of the protamine, blood serum was examined and the hyperglycemia was detected (20).

The study of spatial memory was carried out in an octagonal radial labyrinth.

Ovariectomy caused a deterioration of spatial memory, and the combination of ovariectomy and diabetes deepened the pathological process. In older animals, the study revealed a decrease in spatial memory, and diabetes further aggravated the cognitive function.

Changes that occur after ovariectomy indicate involvement of estrogen in the regulation of cognitive functions in the process and indicate the possibility of using estrogens in the treatment of neurodegenerative changes in premature and age-related menopause and in the context of concomitant pathological processes.

Rusnak V.F., Soni Shivam, Singh Yaduvendra
**TOPOGRAPHO-ANATOMIC FEATURES OF ONTOGENESIS
OF SUPRASPINATUS AND INFRASPINATUS MUSCLES
OF THE POSTERIOR SCAPULAR REGION**

*Department of human anatomy named after M.H. Turkevych
Higher State Educational Establishment of Ukraine
«Bukovinian State Medical University», Chernivtsi, Ukraine*

Muscles of the shoulder girdle have a different internal structure. Muscles are characterized by static and dynamic types of structure. The static, positional action of the muscles strengthens the capsule and is a movable support of the head of the humerus. In the process of growth and development muscle and certain muscle parts are formed in the muscles. During the development of the muscles their internal structure changes.

The supraspinatus muscle covers the blade's hole with the same name and has a single muscular structure of triangular shape, the average muscle width is 47.0 ± 1.0 mm, and in the attachment areas - 24.0 ± 0.6 mm. The total length of the abdominal muscle reaches 137.0 ± 1.4 mm, of which 113.9 ± 2.0 mm in length is occupied by the functional contractile part and 24.0 ± 0.88 mm distal tendons. The contractile part of the muscle is formed by fibers of different lengths, from $43,0 \pm 1,36$ mm to $116,0 \pm 1,8$ mm. The superficial part of the supraspinatus muscle is formed by long, parallel fibers, and the deep part is short, which forms the periosteum of the muscle, which is closely interwoven with the capsule of the shoulder joint. The length of the intramuscular tendon can reach 33.0 mm.

Infraspinatus muscle occupies three-fourths of the infraspinous fossa of the scapula and is divided into three parts: upper and lower surface and deep middle. The Infraspinatus muscle has a triangular shape, with a total length of 174.0 ± 1.4 mm, where the contractile part can reach 151.0 ± 2.2 mm, and the length of the distal tendon is 23.0 ± 0.86 mm. The superficial part of the Infraspinatus muscle consists of parallel muscle fibers, and the deep part is constructed according to the pennate type. The length of the intramuscular tendon is - 58.0 mm.

Herasym L.M., Halahdina A.A.

PERINATAL TOPOGRAPHY OF THE EXTERNAL CAROTID ARTERY

Higher State Educational Establishment of Ukraine "Bukovinian State Medical University", Chernivtsi, Ukraine

The study was performed on 50 specimens of dead fetuses (from 4 to 10 months) and 9 neonates (5 isolated organ complexe sinparticular) with outex ternal signs of anatomical defects orde viations, and with out visible macroscopic deviati ons from the normal structure of the cardiovascular system by means of macro- and micro preparation, making topographic-anatomical sections, blo odves selin jecti ons, X-ray examination, morphometry and statistical process in gof data.

Acervical part of the external carotid artery is found to bea distance from the origin to the poin to fintersection of the stylohyoidmuscle. The following arteries arise from the cervical part of the external carotid artery (upward to the cranial direction): superior thyroid artery, lingual artery, facial artery, occipital and posterior auricular artery. In all the cases the superior thyroid artery deviates from the external carotid artery in the point of bifurcation of the common carotid artery. It has a caudal direction, gives the superior laryngeal artery in the same direction, and approaching to the superior edge of the thyroid gland it is divided dichotomically. The lingual artery emerges from the external carotid artery on the level of the inferior edge of the posterior ventricle of the digastric muscle and passes along the inferior border of the submandibular gland. The facial artery originates from the middle surface of the external carotid artery on the level of the superior edge of the posterior ventricle of the digastric muscle, and passes into the direction of the anterior border of the mastication muscle. Practically on the same level with the facial artery, the occipital

artery originates from the lateral surface of the common carotid artery, passing in the dorsal direction along the inferior border of the posterior digastric muscle. The posterior auricular artery originates from the lateral surface of the common carotid artery higher from the occipital artery. It passes in the dorsal direction along the superior edge of the posterior ventricle of the digastric muscle and inferior edge of the stylohyoid muscle. The middle group of the external carotid artery, that is, branches of the ascending pharyngeal artery is determined in 12% cases at this age period. This kind of topography of branches (major type) of the external carotid artery is found in the majority of observations (77%). In 23% cases an extended type of the external carotid artery branching is determined (extended type – lingual, facial, occipital and posterior auricular arteries emerge from the external carotid artery practically on the same level, that is fan-shaped).

Antoniuk O.P., Sharma Himanshu

THE FORMATION OF PHYSIOLOGICAL ESOPHAGEAL ATRESIA

*Higher state educational establishment of Ukraine
“Bukovinian state medical university”*

Mykola Turkevich Human anatomy department, city Chernivtsi

The occurrence of atresia of the esophagus and tracheo-oesophageal fistula is a consequence of the delay in the reverse development of physiological atresia - the recanalization of the esophagus lumen. However, mechanisms of violation of embryogenesis processes that lead to atresia of the esophagus and tracheo-esophageal fistulas are still unclear. other esophagus occur: 1) agenesis of the esophagus - complete absence of the esophagus, a rare anomaly, which is combined with other severe defects. Instead of the esophagus, there is a connective tissue lobe; 2) hypoplasia of the esophagus (or microesophagus) - a short esophagus. At this time, the stomach may be pushed into the thoracic cavity; 3) macroesophagus (megaesophagus) - an increase in the length and diameter of the esophagus as a result of its hypertrophy; 4) double esophagus (diisophagia). Tuber forms occur very rarely. Sometimes diverticulas and cysts are found which are most often located in the posterior mediastinum, at the level of the upper third of the esophagus; 5) congenital esophageal

stenosis - as a rule, the stenosis is located at the level of the aortic constriction. The esophagus wall is represented by a single-layer cubic epithelium in the basement membrane. From the outside of the basement membrane a layer of undifferentiated mesenchyma is found to be 145-150 μm in thickness. The height of the epithelium is 10-12 μm . The oval cell nuclei are located at different levels: the individual nuclei are apical, part of the nuclei is closer to the base, and most of the cells are in the middle of the cells. Enlargement of the esophagus on transverse sections reaches 7-8 microns. Mesenchymal cell nuclei are located in a layer around the rudiment of the esophagus, and the nuclei of the cubic epithelium, which extend its lumen, are localized at different levels.

Antoniuk O.P., Kumar Amit

THE PECULIARITIES OF MORPHOGENESIS OF DUODENAL ATRESIA IN NEWBORNS

*Higher state educational establishment of Ukraine
"Bukovinian state medical university"*

Mykova Turkevich Department of human anatomy, city Chernivtsi

The frequency of atresia of the small intestine, according to the autopsies, is about 1: 3000, but according to lifetime radiological studies, this figure is significantly higher (1: 6,000 newborns). In the study of the morphology of the duodenum, a preathretic (proximal) segment, an atresia site and a postathretic (distal) segment. Atresia of the duodenum there is a narrowing of its wall (the norm 4-4.1 mm, atresia 2.0-2.2 mm). The thickness of the membrane in the duodenum ranges to 1.5 mm, and in the ileum - up to 0.5 mm. Under the influence of external harmful factors, the process of restoring tubular canals is violated, which leads to atresia. Epithelial gluing of the duodenum in newborns was discovered. Directly the areas of atresia with multiple foci of fibrosis and necrosis indicate the possible origin of disorders of the development of blood vessels, which led to the development of fibrosis in this area of ischemia. This applies to all sections of the intestine, both the thin and the thick (rim) gut at atresia with fibrous strands (type II) and the full form of atresia (type III). Regarding multiple atresia (type IV), in particular, with the "weather"

syndrome, the pathological manifestations are so numerous and significant that in this case the pathology of the development of the intestinal tube as such, in particular, of the bowel movement, becomes in the foreground. In the preatretic segment of the duodenum there was a significant hypertrophy of the circular muscular layer in comparison with the longitudinal, hyperplasia of smooth myositis, a part of fibrosis with a significant number of elements of the fibroblastic series of connective tissue, areas of polymorphonuclear leukocyte infiltration along the blood vessels and in the layers of the connective tissue between the layers of the muscular membrane .

Antoniuk O. P., Gaudia Deepak

**MORPHOFUNCTIONAL CHARACTERISTIC OF THE
CHANGE OF JEJUNAL STRUCTURE DURING ATRESIA.**

Higher state educational establishment of Ukraine

“Bukovinian state medical university”

Mykola Turkevich Human anatomy department, cityChernivtsi

The morphofunctional examination of the intestine affected by atresia is quite relevant both from the point of view of theoretical research in general, and morphology in particular, as well as from the point of view of surgical treatment of intestinal atresia. For greater consistency and systematization of the results of the study, changes in the structure of the atresia, preatretic (proximal) and post-atretic (distal) segments of the intestine were studied. The largest expansion of the small intestine reaches 6-8 mm, in norm 2 times less. The wall of the small intestine is thickened by 1.6 times (the norm is 2-3 mm). When atresia with fibrous strands of type II), the villi are shortened, sometimes flattened, and the lateral surfaces of the tops are covered with epithelium with goblet cells. The height of epithelial cells atresia turns into high prismatic to low. Somewhere in the apex of the villi there is a peeling of the epithelium, which loses its connection with its own plate of the mucous membrane. There is a transition from desquamation of the epithelium to the adhesion of the tops of the villi. Areas affected by atresia, characterized by

significant changes in anatomical structure. The muscular envelope of the organ undergoes almost complete fibrotic degeneration (a considerable amount of fibroblasts, lymphocytic and polymorphic-cell infiltration are localized in the circular muscular layer), multiple sites of necrosis are present. The nuclei of smooth myocytes are enlightened, eosinophilia of the cytoplasm is reduced. The intestinal blood vessels are sharply enlarged, red blood cells are adherent to the walls of the vessels. These are the most severe manifestations of atresia, the complete exhaustion of compensatory mechanisms. Directly the areas of atresia are alternating foci of fibrosis and necrosis, where it is difficult to assess the condition of any elements of the intestine. However, it is known that fibrosis and the resulting stenosis with the transition to complete atresia may be due to local ischemia and hypoxia caused by it.

With full form of atresia (type III) in the segment of the colon, the number of cells increases, especially in the lateral surfaces of the villi. The epithelium in the gut wall is preserved, but the number of cell-like cells increases. This is due to the increased functional activity of the epithelial cells, as well as their permeability, due to swelling of the gut wall. Consequently, the morphological data once again confirm the vascular theory of the development of intestinal atresia. In this case, they relate to atresia with fibrous strands and complete intestinal atresia. In atresia with fibrous strands (type II) in the preatretic segment of the intestine there is a shortening of the villi, which in some places are tilted to one side and flattened. The lateral surfaces of the villi are covered with a large number of cell-like cells, at the tips of the villi of the epithelium depleted.

Besplitnik M.G., RudiukO.G.

**WAYS OF LETTING OF THE LYMPH FROM
LUMBAR-SACRAL PLEXUS**

*Higher state educational establishment of Ukraine
“Bukovinian state medical university”*

Department of human anatomy named after M.H. Turkevych

From data of literature it is known that by the lymph nodes of the first and next orders for the initial lymphatic vessels of lumbar-sacral plexus there are knots that enter in the complement of their collector discharge lymphatic ways.

In lumbar and sacrum nerves that enter in the complement of lumbar-sacral plexus, in accordance with their structure, lymphatic capillary vessels spread as a net for to the connective tissues layers that surround nervous pinches. Lymphatic vessels that form nets in an epineurium adhering to motion of blood vessels, form loops that have a form of oval. In the areas of confluence inter se three or four vessels in nets appears accordingly три- or quadrangular form of expansion of lymphatic river-bed.

As a result of the successive merging of lymphatic capillaries between themselves, intra-trunk initial tubular lymphatic vessels of a larger caliber, which follow the course of blood vessels in the ascending and descending directions to the point of their fusion and exit from the nerve trunks, are formed. Intra-trunk lymph lumbo-sacral plexus are connected by continuous anastomoses both throughout a separate nerve stem, and in the joints of adjacent nerve branches in the loops of the lumbo-sacral plexus. The largest intra-trunk arterial vessels are surrounded by small petalous pervascular lymphatic plexuses.

Thus, we can conclude that the pathways of lymph outflow from the initial sections of the nerve trunks of the lumbo-sacral plexus are formed by a network of lymphocapillars giving rise to the primary vessels that merge into the collector vessels of the regional lymph nodes.

Besplitnik M.G., Rudiuk O.G.
INNATE SCOLIOTIC ILLNESS

*Higher state educational establishment of Ukraine
“Bukovinian state medical university”*

Department of human anatomy named after M.H. Turkevych

By a feature innate scoliosis there is that his development and progress coincide with the period of height of child, deformation arises up on more limit area, and anti-curvature has more declivous arc. Dysplastic scoliosis arise up on a background an excalation lumbar-sacral department of backbone, one-sided sacralization or lumbalization. Dysplastic scoliosis show up for children after 8-10-years-old age and quickly make progress, as coincide with the next push of height. Basic arc it is a bend on the lumbar department of backbone.

As a result of scoliotic deformation there are anatomical and physiological disorders of organs of thorax : an increase grows first of all intrapulmonic pressure due to the compression of lungs on a concave side and scray expansion on a protuberant side with development of the emphysematous phenomena. It becomes reason of growth in the small circle of intravascular pressure that stipulates the overload of right half of heart, the muscle of that is more weak, than on left to the half. In myocardium of right half of heart a hypertrophy that develops at first on a background a hypoxia progressively results in arising of myocardial dystrophy out of by the decline of functional possibility of right half of heart. The increase of intrapulmonic pressure results in growth oligotrophies of right heart, and change to the landmark of heart - to violation of exit of vessels from a heart what increases loading on the function of the left half of heart, where a hypertrophy develops too.

Thus, there are heavy anatomic changes not only of backbone at a scoliosis thorax, but also pelvis, lower limbs. In addition, making progress anatomic-functional violations stipulate growth of pathological changes of organs of thorax, worsening of general of patient. On that ground a scoliosis is examined not only as a disease of backbone, but as scoliotic illness of organism.

Besplitnik M.G., Rudiuk O.G.

FEATURES OF SPINAL DISRAPHISM

Higher state educational establishment of Ukraine

“Bukovinian state medical university”

Department of human anatomy named after M.H. Turkevych

To the group of spinal disraphism belongs mean on group of innate anomalies of development of backbone and spinal cord. Thus it follows to mark hidden spinal disraphism (Spina bifida occulta), when it is not violation of integrity of the cutaneous covering is above a defect vertebrae and open breaking up of backbone, at that the broken integrity of the cutaneous covering is above the unco-ossified area of backbone with forming of the hernia thrusting out, content of that can be a spinal cord and his shells.

Spina bifida arises up on 3-4 weeks of pregnancy and it can to be not only in the isolated kind but also to combine with other defects of the nervous system. Among the negative factors of influence in relation to an origin Spina bifida it follows to mark the inherited factors, in particular inherited genetic defect from one of parents and unfavorable factors of environment.

Diagnostics of spinal disraphism is important and by a social task, as for children with such anomalies characteristic is violation of statukinetic to development, functions of pelvic organs with the problems of adaptation in society. Such consequences can be avoided by means of the timely breaking of pregnancy or surgical corrections of anomaly are in an early postnatal period.

Thus, optimization of prenatal and postnatal diagnostics, introduction of new technologies, establishment of clinicomorphological features of innate development defects with a defeat of the central nervous system for children and prognostic meaningfulness of risk of their forming factors with creation of the complex system of grant diagnostically of prognostic and medical and preventive help presents one of main and perspective directions of modern medicine.

Kryvetskyi V.V., Besplitnik M.G.

**FEATURES OF VASCULARIZATION OF THE SPINE
IN FETAL PERIOD AND NEWBORNS**

*ENEА “Bukovinian State Medical University”, Chernivtsi, Ukraine
Department of human anatomy named after M.H. Turkevych*

The arteries of front surface of bodies of cervical vertebrae anastomosed inter se. Transversal anastomoses are especially expressed. Already in the second half of prenatal development in the structure of arteries what blood supply cervical vertebrae, it is observed individual changeability is well expressed, segmentation is clearly determined in the blood supply of separate vertebrae, although the sources of their blood supply the main arteries of mainly vertical direction serve as.

The upper three pairs of back intercostal arteries have in the pectoral department of spine oblique-vertical direction only, other intercostal arteries are situated horizontally. Arteries of front and back surfaces of bodies of vertebrae in fetus, newborns and children of first-year of life more calculation and anymore branch out than for adults. The longitudinal prevail on the front surface of bodies, and on back are both longitudinal and transversal interarterial anastomoses.

In the lumbar department of spine lumbar arteries, as well as greater part of intercostal, occupy horizontal position. Thus their last pairs can have oblique-descending direction. From the branches of these arteries more numerous, that are situated on the front surface of bodies of vertebrae. On their back surface of arteries less than and they thinner than in a pectoral department, because one lumbar artery can participate in the blood supply of two-three vertebrae.

The sources of blood supply of sacrum and coccygeal departments in fetus, newborns and adults fully gather, but at fetus more developed and large is a middle sacrum artery. Lateral sacrum arteries can have the high and subzero beginning, branch along all aitchbone only in overhead or only in his lower half.

Vepriuk Yu.M., Kashperuk-Karpivk I.S., Rykhlo I.S., Prunchak V.

THE ECOLOGY AND FEATURES OF HOUSEPLANTS

Higher State Educational Establishment of Ukraine

«Bukovinian State Medical University», Chernivtsi

Thanks to evolution, many colorful plants and flowers have become the attractive species we know and love today. Without any doubt, flowers help us better to know and understand colors and paints of today's world. Flesh plants and flowers, which give us plenty of positive emotions and excellent mood, are the essential part of our spirit. The history of flowers arrangement dates back to ancient Egypt, Greece and China. Greeks, for example, used them as a decoration in the form of various interpretation, that's why Temples of ancient Hellas were adorned with flowerpost, garlands and wreaths made of flowering plants.

The age of discovery gave us different ways to the development of new kinds of flowers, their schemes of classifying and their origin.

The purpose of our project was to identify specific kinds of houseplants in educational institutions, to get acquainted with them; to determine ecological groups of plants and their peculiarities and to identify how to keep houseplants in auditoria in a proper way.

The air in inside, for various reasons, is full of toxic substances, so the main task of houseplants is to improve indoor air quality. Also, some kinds of houseplants help to cope with the aggression of civilized world. Scientific researches have shown that indoor plants filter out more than 300 volatile organic compounds (photogenic factor), which have an influence on our health. Moreover, indoor plants can reduce carbon dioxide level, increase humidity and reduce airborne level.

Among them are phytoncids – biologically active substances, which prevent growth and development of bacteria's in the air and decrease stress hormone levels. Indoor plants can reduce components of indoor air pollution, particularly volatile organic compounds (VOC) such as benzene, trichlorethylene and formaldehyde. Some kinds of brakes, ivies, palms, sansevera and alone vera are known as the most popular phytoncids. It is relevant to mark that aloe and ivy, have bactericidal and

antiseptic features. Also, geranium disinfects air in a good way and can kill streptococcus and staphylococcus at the same time. Chemicals of geranium can prevent stress, insomnia and necrosis and have depressant and anti-stress. Conifers produce wholesome for our health negative ions of oxygen, which can counteract the action of household appliance, especially computers and televisions.

Cactus is one of the most salutary plants, especially with long needles. This plant has bactericidal effect, however, there is one more vital feature which cactus has. From literature sources, it is known that cactus needles have an attribute to ionize air, which is really useful for our health. But it is necessary to admit that spathiphyllum, syngonium, scindapsus ionize air more intensive. Scientists have made a measurement of electromagnetic radiation near the computer monitor. The result has shown that cactus does not protect people from this kind of radiation.

Thus, specific diversity of houseplants in educational institution comprises various ecological groups of plants and their particularities, which demands the ability of locating in right place.

Vepriuk Yu.M., Tovkach Y.V., Rykhlo I.S., Blahun S.

THE ECOLOGY OF ROOM FLORICULTURE

Higher State Educational Establishment of Ukraine

«Bukovinian State Medical University», Chernivtsi

The most perfect and accessible way of knowing colours and paints, without any doubt, are flowers. Flesh flowers, which give us plenty of positive emotions and excellent mood, are the essential part of our spirit. History of flowers arrangement dates back to ancient Greece, that's why Temples of ancient Hellas were adorned with flowerpots with gorgeous blossoms in each. The age of discovery gave us different ways to the development of new kinds of flowers, their schemes of classifying and their origin.

The aim of our project was to get acquainted with specific kinds of houseplants in educational institutions, to identify ecological groups of

plants and their particularities and to determine how to keep houseplants in auditories.

The air in close premisses, for various reasons, is full of toxic substances, so the main task of houseplants is to improve indoor air quality. Also, some kinds of houseplants help to cope with the aggression of civilized world. Scientific researches have shown that indoor plants filter out more than 300 volatile organic compounds (photogenic factor), which have a beneficial influence on our health.

Among them are phytoncids – biologically active substances, which prevent growth and development of bacteria and airborne microbes in the air. Indoor plants can reduce components of indoor air pollution, particularly volatile organic compounds (VOC) such as benzene, toluene and formaldehyde. Some kinds of brakes, ivies, palms, sansevera and alone vera are known as the most popular phytoncids.

Amid indoor plants, which have bactericidal and antiseptic features, it is relevant to mark out aloe, ivy, etc. For example, geranium disinfects air in a good way and can kill streptococcus and staphylococcus at the same time. Substances of geranium has depressant and anti-stress properties and its aroma has a sedative effect and can prevent stress, sleeplessness or necrosis. Conifers produce wholesome for our health negative ions of oxygen, which can counteract the action of household appliance, especially computers and televisions. One of the most salutary plant is cactus, especially with long needles. This plant has bactericidal effect, however, there is one more vital feature which cactus has. From literature sources, it is known that cactus needles have an attribute to ionize air, which is really useful for our health. But it is necessary to admit that spathiphyllum, syngonium, scindapsus ionize air more intensive. Scientists have made a measurement of electromagnetic radiation near the computer monitor. The result has shown that cactus does not protect people from this kind of radiation.

Thus, specific diversity of houseplants in educational institution comprise various ecological groups of plants and their particularities, which demands the ability of locating in right place.

Vepriuk Yu.M., Proniaiev D.V., Rykhlo I.S., Sirochenko O.
**EFFECT OF XENOBIOTICS ON KIDNEY'S FUNCTIONS IN
MATURE AND IMMATURE RATS UNDER CONDITIONS
OF PINEAL GLAND HYPO-AND HYPERFUNCTION**

*Higher State Educational Establishment of Ukraine
«Bukovinian State Medical University», Chernivtsi*

Influence of heavy metals on the human body leads on the development and progression of pathological changes. Xenobiotics such as aluminum and Lead have significant nephrotoxic action and violate the significant functional changes in activity of this organ.

In recent years the health of the population of Ukraine is much worse, due to anthropological pollution, in particular, compounds of aluminum, of which subjected every day each of us.

In experiments on 96 mature and immature males nonlinear white rats was studied the influence of hypo - and hyperfunction of pineal gland and the effect of 14 days introduction of aluminium chloride solution on renal function parameters.

Investigation of environmental Lead accompanied nephrotoxic effects on the kidneys, characterized by the development of proteinuria and loss of sodium in the urine due to damage of tubular nephron was found. Pineal gland hypofunction causes more significant nephrotoxic effect of aluminum salts in kidneys of mature rats with significant proteinuria and a manifestation of a syndrome of sodium loss in the urine.

But under condition of pineal gland hyperfunction nephrotoxic effects of aluminum salts were less significant, probably due to higher levels of antioxidant "hormone of darkness" – melatonin.

Vepruk Yu.M., Proniaiev D.V., Rykhlo I.S.
**THE ROLE OF EXOGENOUS MELATONINE ON INDEXES
OF RENAL FUNCTIONS UNDER THE CONDITIONS
OF COMBINE INFLUENCE OF XENOBIOTICS**

*Higher State Educational Establishment of Ukraine
«Bukovinian State Medical University», Chernivtsi*

It is well-known, that the basic mechanism of melatonin action is antioxidative. Melatonin is the donor of electrons, synergist of various ferments, powerful oxidant which protects nuclei cells from damages, stimulates an activity of antioxidant ferments, links free radicals and provides a defense for protein molecules from oxidative damage. Also, this hormone is one of the basic molecules, which protects full organism from oxidative stress and can perform protective properties on nephron tubules.

Data analysis of melatonin on indexes of excretory and acid regulatory renal functions in mature rates under the conditions of combine influence of aluminium and plumbum salts, has shown that level of diuresis against the background of melatonin introduction was lower on 11% ($p < 0,01$) in comparison with control group of animals. Indicators of potassium ions concentration in urea on the background of melatonin introduction were lower in 2,2 times ($p < 0,05$) and the excretion of potassium ions was also lower in 2,3 times as to control, which points out to the lack of tread influence of given factor under these circumstances. Indicators of creatinine concentration in urea were lower on 27% ($p < 0,005$) than in control. Indexes of tubules filtration, concentration of protein in urea and its excretion and also relative reabsorption of water have not changed amount group comparison. It was detected growth of hydrogen concentration in urea ($p < 0,001$) and ammonium coefficient in 3,6 times ($p < 0,001$) with the use of melatonin in mature animals.

Thus, changing in indexes of creatinine concentration, ions of hydrogen and ammonium coefficient in urea, points out to protective influence of melatonin on proximal pars of nephron with some reductions of tubuloglomerular feedback reactivity.

Vepriuk Yu.M., Yakovets K.I., Rykhlo I.S.

**CHARACTERISTIC OF HOMEOSTATIC RENAL FUNCTIONS
IN MATURE AND IMMATURE ANIMALS**

*Higher State Educational Establishment of Ukraine
«Bukovinian State Medical University», Chernivtsi*

To the homeostatic renal functions belong excretory and acid regulatory one, which have some differences in mature and immature rats. These differences are often due to the insufficient maturity of nephron tubules, juxtaglomerular and regulatory mechanisms in immature animals and also reactions of lipids peroxidation, level of which essentially depends on endogenous melanin concentration.

Data analysis of excretory and acid regulatory renal functions in mature and immature rats showed that the level of diuresis in immature rates was on 45% ($p < 0,001$) lower, in comparison with mature animals. Also, indicators of concentration in mature animals were lower on 55% ($p < 0,05$), excretion of creatinine was lower on 58% ($p < 0,02$) and the excretion of protein, was lower on 57% ($p < 0,001$). The concentration of creatinine in urine was not much different among groups comparison, however the excretion of creatinine was lower in immature rates in contrast with mature animals. Glomerulus filtration had a tendency towards retardation in immature rates. The concentration of protein in urine among groups comparison has not changed significantly, besides the excretion of protein in immature rates was a bit lower.

It is an interesting fact that in immature animals the excretion of ammonia was on 44% ($p < 0,001$) lower and the ammonium coefficient was lower in 2,5 times ($p < 0,001$).

Thus, detected differences of excretory and acid regulatory renal functions in age group of animals are probably conditioned by certain particularities of nephron tubules development in ontogenesis.

Vepriuk Yu.M., Kashperuk-Karpiuk I.S., Rykhlo I.S., Kozoriz V.
**CHARACTERIZATION OF HOMEOSTATIC FUNCTIONS
OF KIDNEYS IN MATURE AND IMMATURE ANIMALS**

*Higher State Educational Establishment of Ukraine
«Bukovinian State Medical University», Chernivtsi*

The kidneys play an important role in maintaining homeostatic by regulating the concentration and volume of body fluid. The homeostasis of kidneys consists of two main functions such as excretory and acid regulatory one, which have some distinctions in mature and immature rats. These differences are often based on the lack maturity of nephron tubules, regulatory and juxtaglomerular mechanisms and also the reactions of lipids peroxidation, the level of which mainly depends upon concentration of endogenous melatonin.

An analysis of data on acid regulatory and excretory renal functions in mature and immature rats showed excretion of kreatinine was lower on 58% ($p < 0,02$) and the excretion of protein, was lower on 57% ($p < 0,001$). The size of diuresis in immature rates was on 45% ($p < 0,001$) lower in comparison with mature animals. Also, the concentration of kreatinine in urine didn't differ considerably in comparison groups, however the excretion of kreatinine was lower in immature rates in contrast with mature animals. The indicators of concentration in mature animals were lower on 55% ($p < 0,05$). The concentration of protein in urine in comparison groups didn't change significantly, besides the excretion of protein in immature rates was lower. Glomerulus filtration had a tendency to inhibition in immature rats.

The interesting point is that the excretion of ammonia was on 44% ($p < 0,001$) lower and the ammonia ratio was lower in 2,5 times ($p < 0,001$) in immature rats.

Therefore, certain specificity of development of nephron tubules in ontogenesis can cause distinctions of excretory and acid regulatory functions of kidneys in mature and immature rats.

Vepriuk Yu.M., Sorohan M.M., Rykhlo I.S., Pontyk M.
**THE IMPACT OF EXOGENOUS MELATONIN ON INDICES
OF RENAL FUNCTIONS UNDER THE INFLUENCE
OF COMBINED EFFECT OF XENOBIOTICS**
*Higher State Educational Establishment of Ukraine
«Bukovinian State Medical University», Chernivtsi*

The main function of melatonin, as it is known, is an antioxidative one. Melatonin is the synergist of various ferments, donor of electrons, powerful oxidant which protects nuclei cells from damages, stimulates an activity of antioxidant ferments, links free radicals and provides a defense for protein molecules from oxidative damage. Moreover, protects full organism from oxidative stress and can perform protective properties on nephron tubules.

The analysis of the data of melatonin effect on indexes of excretory and acid regulatory functions of kidneys in mature rats under the conditions of combine influence of aluminum and lead salts, has shown that the concentration of potassium ions in urea were lower in 2,2 times ($p < 0,05$) and the excretion of potassium ions was also lower in 2,3 times as to the control, which points out the lack influence of given factor under these circumstance.

The level of diuresis against the background of melatonin introduction was lower on 11% ($p < 0,01$) as to the control. The concentration of kreatinine in urea were lower on 27% ($p < 0,005$). The indices of tubules filtration, concentration of protein in urea and its excretion and also relative reabsorption of water didn't really differ in comparison groups. We detected the growth of ammonia ratio in 3,6 times ($p < 0,001$) and the growth of hydrogen concentration in urea ($p < 0,001$) in mature animals.

Therefore, detected changes in concentration of kreatinine, ions of hydrogen and ammonia ratio in urea indicates that the melatonin has a protective impact on proximal parts of nephron with some demotions of tubuloglomerular feedback reactivity .

Vepriuk Yu.M., Tovkach Y.V., Rykhlo I.S., Stankevych K.
**THE IMPACT OF XENOBIOTICS ON RENAL FUNCTIONS
IN MATURE AND IMMATURE RATS UNDER CONDITIONS
OF PINEAL GLAND HYPO-AND HYPERFUNCTION**

*Higher State Educational Establishment of Ukraine
«Bukovinian State Medical University», Chernivtsi*

Heavy metals toxicity has proven to be a basic threat that can cause progression of pathological changes and several health risks. Xenobiotics such as aluminum and lead have significant nephrotoxic effect and violate the significant functional changes in activity of our organs.

Over the past few years, Ukraine face worsening of population, owing to anthropological pollution, in particular, compounds of aluminum, of which subjected every day each of us.

The experiment involved 96 nonlines white male mature and immature rats. We studied the impact of hypo - and hyperfunction of pineal gland and the effect of 14 days introduction of aluminum chloride solution on renal function.

Investigation of environmental lead accompanied nephrotoxic effects on the kidneys, characterized by the development of proteinuria and loss of sodium in the urine due to damage of tubular nephron that was found. Hypofunction of pineal gland causes more significant nephrotoxic effect of aluminum salts in kidneys of mature rats with significant proteinuria and a manifestation of a syndrome of sodium loss in the urine. However, under condition of pineal gland hyperfunction nephrotoxic effects of aluminum salts were less significant, according to the higher levels of antioxidant melatonin.

Protsak T.V., Ostapenko I.V.

CONGENITAL MALFORMATION PANCREAS

M.H. Turkevych Department of human anatomy Higher State Educational Establishment of Ukraine «Bukovinian State Medical University», Chernivtsi

Relevance: malformation pancreas is rarely studied, although it is the cause of tumors, acute and chronic pancreatitis in adults. For example, the frequency of pancreatitis associated with malformations of the pancreas is about 0.1%. Pancreas divisum is the most common congenital anatomic abnormality of the pancreas. Incomplete pancreas divisum, is infrequent, and presents as a narrow and often inadequate connection between the dorsal and ventral pancreatic ducts, with the majority of drainage occurring via the smaller minor papilla. Autopsy series have reported the incidence of pancreas divisum to be in the order of 5-10% of the general population. Although pancreas divisum is a congenital anomaly present at birth, it is often not diagnosed until the fifth decade of life, when it becomes symptomatic. With increasing use of cross-sectional diagnostic imaging, pancreas divisum is being diagnosed earlier in asymptomatic patients. In typical Pancreas divisum, the fusion of the dorsal and ventral ductal systems fails, forming two distinct conduits with the dorsal duct draining the majority of the pancreas via the minor papilla and the ventral duct draining only the inferior portion of the head of the pancreas via the major papilla. Agenesis of the dorsal pancreas is more common than ventral agenesis. Pancreatic hypoplasia refers to congenital underdevelopment of pancreas and is often referred to as partial agenesis of the pancreas. It is a rare congenital anomaly. This agenesis can involve the ventral or dorsal anlage. Severe hypoplasia of the pancreas can be associated with mutations involving the HNF1 β gene. The common clinical presentation is abdominal pain, which may be nonspecific or secondary to pancreatitis. Recurrent pancreatitis is quite common. Many patients present with diabetes mellitus. Sometimes, the patient may present with steatorrhea or other signs of exocrine insufficiency.

Marchyk O.F., Protsak T.V., Hovanets K.R.
**THE DEVELOPMENT OF UROGENITAL SYSTEM
IN HUMAN EMBRYOS**

*M.H. Turkevych Department of human anatomy Higher State
Educational Establishment of Ukraine «Bukovinian State Medical
University», Chernivts*

At the end of the embryonic period, the reduction of the cranial part of the primary kidney begins. At the same time the process of obliteration of the mesonephric appropriate vessels, which is manifested by a sharp decrease in their lumen. The process of reduction of blood vessels commonly begins with their intraorganic part. At the same time, the lumen of mesonephric vessels in the places of their branching from the aorta remains almost identical throughout. This suggests that the vascular factor does not play an essential role in the reduction of mesonephros. However, it should be noted that the lumen of mesonephric vessels, which provide blood supply to the gonads slightly increases. At this stage of development, the hilus of the gonads begins to form.

Large round cells with an optically transparent cytoplasm – oocytes are seen within medullary cords. The initiation of the formation of gonadal thin tendons, directed towards the cortical substance, are visualized within the medulla of the gonads. As a result of mass settlement of the sexual cells of the sexual glands of the mesenchyma of the latter is poorly expressed, the connective tissue capsule of the gland is absent. The process of separating gonads from mesonephros continues. In the place of their close contact a cluster of small cells of mesenchyma is seen no sexual cells were detected, which should be considered as the beginning of the formation of the medullary substance of the ovary.

In the embryonic period, occurs the intensive development of the gonads, and this leads to an increase in their length, width and thickness. At the end of this period in the central part of the sexual glands there are barely visible cords to the clotting epithelium of the organ. This is the first phase of formation of gonadal cords. The stage of the formation of cords in the gonads should be considered one of the critical periods in their development.

Tovkach Yu., Skakun A.G, Fundiur V., Paholka L., Bizer L., Zapolska O.
**PECULIARITIES OF MICROANATOMY OF THE UPPER JAW
INJURIES IN RATS**

*Higher state educational institution of Ukraine «Bukovinian State
Medical University” ChernivtsiDepartment of Anatomy, Topographic
Anatomy and Operative Surgery*

The specific gravity of the maxillofacial lesions constitutes 21-40%, that points out to the further study of this problem.

Dystrophic changes with focus destruction of the membranous and intracellular structures.were observed during the electron-microscopic investigation in the ultrastructural organization of osteoblasts. 14 days following the rats’jaw injury, condensation of chromatin in the nucleus and enlightenment of its matrix is kept under the electron-microscopic study of osteoblasts. Nuclear membrane had the centers of destruction. Mitochondria had a clearly-outlined outer membrane and crystals. Matrix of mitochondria becomes a fine granular structure. At the same time, centres of destruction both membranes, and crystals occur not rarely.

Cisterns of granular endoplasmic reticulum are expanded, their contents are electron-transparent from the cells of the lysis of its membranes.

The number of ribosomes, associated with the membranes of the endoplasmic reticulum, as well as the ribosomes and polysomes, located freely in the cell cytoplasm, is significantly greater than in the previous observation period. In the osteoblastic cytoplasm, hyperplasia of granular endoplasmic reticulum is observed. Numerous ribosomes, becoming a typical structure, were localized on the membranes of the granular endoplasmatic reticulum. In comparison with the preceding term, the number of free ribosomes and polysomes increases.

Tovkach Yu.V., Vepriuk Yu.M., Slobodianiuk K.

PATHOLOGY OF THE CERVIX

Higher State Educational Establishment of Ukraine “Bukovinian State Medical University” Department of Anatomy, Topographic Anatomy and Operative Surgery

Pathology of the cervix is the one of the most actual in the modern medicine, because requires close attention not only obstetrican-gynecologists, but also oncologists and other professionals, as in etiopathogenesis of cervix disease progression, significant role are playing viral and bacterial infections condition of the local and systematic immunity. In the structure of the gynecological diseases in Ukraine, this pathology has the second place and seventh among all malignant neoplasms in the world. This is due to early initiation of sexual activity, large number of extramarital contacts, traumatizm in birth, chronic inflammatory diseases of the vagina and cervix, and, accordingly, also an increase of the number of sexually transmitted diseases, including viral genesis, role of which in cervical cancerogenesis are beyond any doubts. One of the most important achievements in the study of cervical cancer development is the recovery of the etiological factor – HPV and its influence on its occurrence and the development of precancerous diseases of the cervix, their further transformation into cervical cancer. According to V.V. Sopol, V.O. Khudobyak, Y.B. Boychuk .Accordin to National cancer-registry (2006), annually in Ukraine from cervical cancer dies approximately 2500 women, about 500 of them are employable. According to WHO data, cervical caser is detected almost in 500 000 women annually. In Ukraine over last years (2008-2010) there is a tendention to decreasing of letal indicators, up to one year, that indicates about higher number of sick people who were detected in inception phase of cervical cancer. It became possible thanks to the “Screening of cervical pathology program” in Ukraine, which was accepted for 2005-2010 years. Its purpose was prompt diagnosis, examination and adequate treatment of patients with pre-tumorous pathology of the cervix. However, there is a clear tendency to the development of the disease in young women underthe age of 30-40, according to, L.I.Vorobyov’s data, 2010. The best methods for treating background diseases in young women, who have never gave birth, and those, who combine effective influence on the

pathological process with the absence of traumatic damage to the cervix, and those who do not implement a negative impact on women's reproductive health and future births. According to Kupchak I.M.

So, the detection of pathology of the cervix is still at the stage of pregnancy planning, because during it doctors are limited in diagnostic and therapeutic measures. Beginning any activity in pregnant women with pathology of the cervix should be from the definition of the vagina's microbiocenosis features and cervical canal, sensitivity of microbial agents found to antibiotics and holding of adequate sanitation. The course of labor in women with benign pathology of the cervix is often complicated by: pre-term birth, weakness of labor activity, cervical raptures, etc. Regression of benign pathology of the cervix depends on the nature of the defeat, the parity of the birth, the method of labor widening, the cervix birth injury, the state of local immunity and the microflora's species spectrum. There is a need to develop a complex of therapeutic and diagnostical measures to improve the obstetric and prenatal aspects for women with benign pathology of the cervix in history. According to Bisaga N.Y.

Kashperuk-Karpiuk I.S., Ivancheskul A.I., Bizer L., Zapolska O.
**ANATOMIC FEATURES OF ELECTRONIC MICROSCOPY IN
LABORATORY ANIMALS ON THE 7TH DAY AFTER A
POLYTRAUMA**

*Higher State Educational Establishment of Ukraine "Bukovinian State
Medical University" Department of Anatomy, Topographic Anatomy and
Operative Surgery*

At present, the proportion of maxillofacial lesions is 21-40% with an increase in the number of fractures of the bones of the face and damage to the bone and muscle apparatus by 10-15%, which should be taken into account when choosing therapeutic tactics. There is a need to study the anatomical features of violations and reactive changes in the system of the extra- and intraorganic vascular bed and the efferent innervation of muscles of the jaw apparatus of people of various constitutional features of animals with scientific justification based on the comparison of electromyography data. In the I group of animals, 7 days after the simulation of the polytrauma

of the mandible during the electron microscopy study in the ultrastructural organization of osteoblasts, there were dystrophic changes with cellular degradation of the membrane and intracellular structures. A significant number of osteoblasts contained nuclei that had somewhat elongated round shape. The nucleus matrix in most osteoblasts acquires low electron density. Chromatin granules were concentrated on the inner membrane of these cells in the form of osmophilic depths. Nuclear membrane is substantially loose. She lost a well-structured structure. Sometimes there was a rather deep invagination of the nuclear shell. Quite often it was possible to observe numerous cells of the lysis of the nuclear membrane. Osteoblastic cytoplasm contained a small amount of organelles. Mitochondria were located predominantly in the perinuclear zone of the cytoplasm. They were swollen and contained an electron-transparent matrix. The number of crysts in them is significantly reduced, quite often there was a lysis of external membranes and mitochondria crust. Granular endoplasmic reticulum tanks in the vast majority of cells were expanded and contained an electron-transparent substance. On the membranes of granular endoplasmic reticulum, only isolated ribosomes were detected. In some osteoblasts, the membranes of the granular endoplasmic reticulum had regions of destruction.

Lamellar cytoplasmic Golgi complex was subjected to reduction. It was a smooth membrane that was individually located in the cytoplasm and rather large electron-transparent vacuoles of irregular shape. Primary and secondary lysosomes were detected in the area of the localization of the lamellar cytoplasmic Golgi complex. There was a decrease in the number of freely located in the cytoplasm of ribosomes and polysomes. Sources of literature do not give a complete picture of a number of important aspects of the problem of injury with predominant damage to the maxillofacial area, because the works are descriptive and only partially reveal the scattered data.

Ezhned M., Horoshko A., Matuschak M., Sakhatska I., Kostyshyn L.
ESTABLISHING THE HYPOGLYCEMICEFFECT

OF DANDELION AND ELECAMPANE COMBINED ROOTS EXTRACT DEPENDING ON DOSE

*Higher State Educational Establishment of Ukraine
"Bukovinian State Medical University", Chernivtsi*

Department of Pharmaceutical Botany and Pharmacognosy

Diabetes mellitus (DM) is one of the most common diseases and has become a serious problem. In developed countries it reached 4-5% of the total population. Every 10-15 years the number of patients with diabetes is doubled. Along with the traditional methods of treating diabetes the phytotherapy nowadays is gaining in popularity. Medicinal plants have a number of advantages over synthetic drugs, since they are low-toxic, accessible, cost-effective, have soft effect and can be used without significant side effects, well combined not only with each other but also with synthetic medicines. Therefore, the search for effective drugs for the treatment and prevention of DM and its complications is one of the most important medical and social tasks of modern pharmacology.

The aim of our work was to establish the dose of dandelion and elecampane combined roots extract under conditions of glucose tolerance test by means of single intraperitoneal introduction of glucose.

The experimental animals were divided into two groups, which, in turn, contained several subgroups. 1st group of animals received extracts in the dose from 0.09 to 0.11 g / kg, the average dose of the group was $0,055 + 0.055$ g / kg. 2nd group received extracts in a dose from 0.54 to 1.1 g / kg, the average dose in this group was $0.55 + 0.55$ g / kg.

According to the results of previous experiments it has been proved that the most effective hypoglycemic effect is expressed by elecampane roots and rhizomes extract in the dose of 0.11 g / kg, and dandelion roots exact - 0.1 g / kg. Thereby the animals of the first group received a combination of elecampane and dandelion extracts in the dose 0.11 g / kg + 0.1 g / kg respectively. This group consisted of 8 subgroups. According to the results of the experiment, it was found that in all combinations, the hypoglycemic effect was higher in comparison with the action of "Arfazetin". The best dose of extracts was in the ratio of 0.1 + 0.08 g / kg, which is 1.63 times higher than the reference drug "Arfazetin". In the course of researches, it was found that dose increasing leant to the reduction of the hypoglycemic activity of extracts. Therefore, the next

stage of experiments included research of the combined extract action with decreasing its dose. The animals of second group, which consisted of 6 subgroups, received the combined extract in the dose of 0.1 g / kg (0.05 + 0.05 g / kg). In all animals of this group, after administration of extracts, glucose levels were significantly reduced compared with untreated animals. The combination of dandelion and elecampane extracts in the dose of 0,055 + 0,055 g / kg respectively recovered the glucose values to the baseline level of 1.24 times in comparison with the pathology in 1.69 times the best. The hypoglycemic effect in this experimental group was the best.

Thus, the greatest hypoglycemic effect, according to the results of the experiment, was showed by the combination of dandelion and elecampane the extracts in the dose of 0,055 + 0,055 g / kg, which is proved experimentally as compared with the initial data (1,24 times) and control group (in 1, 69 times), and compared with the "Arfazetin" introduction, the hypoglycemic effect was greater by 19.2% or 1.9 times.

Horoshko A.

PERSPECTIVES OF THE QUERCETIN DRUGS USE IN MEDICINE

*Higher State Educational Establishment of Ukraine
"Bukovinian State Medical University", Chernivtsi*

Department of Pharmaceutical Botany and Pharmacognosy

In recent years, herbal drugs are gaining in popularity in the pharmacotherapy of many diseases. The interest in the use of medicinal plants is due to the fact of when they are properly dosed, they are practically non-toxic, harmless, relatively affordable, effective and the significant resources of raw materials make them a promising subject of research with the aim of developing new herbal drugs. Recently, great attention is paid to quercetin due to its diverse biological effects and the possibility of application in various diseases and pathological conditions. The broad spectrum of biological effects of quercetin is associated with antioxidant and antiradical activity, but the use of quercetin' oral forms can not be considered as optimal, since it is limited to low bioavailability, high biodegradation of its substance. This concept became the basis of the

development of new water soluble quercetin containing drugs - "Corvitin" and liposomal "Lipoflavon" and "Lipoflavon-neo".

The aim of the work was to study some aspects of the quercetin' drugs effect on the pro- and antioxidant balance in the rat's body under conditions of model pathology.

Materials and methods: 35 nonlinear rats were randomly divided into next groups: the first group received 50% glycerol solution at a dose of 10 mg / kg (model pathology), the second and third groups were administered liposomal lipoflavon and soluble lipoflavon, the fourth group of animals was injected "Corvitin" at a dose of 10 mg / kg (in terms of quercetin) once intravenously after 40 minutes after glycerin introduction.

To study the drugs' effect on the intensity of oxidative modification of proteins, studies were carried out to determine these products in the renal tissue, as well as changes in the activity of the enzyme component of the antiradical glutathione system, and the non-enzymatic content of the sulfhydryl groups. Thus, the content of OMB in renal tissue increased in animals of the model pathology group by 1.9 times compared with the control group of animals. The glutathione peroxidase activity in renal tissues decreased in the group of untreated animals by 2.5 times. The introduction of liposomal and soluble lipoflavon recovered this index, which was by 1.34 and 1.78 times, the administration of corvitin increased this figure by 1.52 times. The content of sulfhydryl groups in treated animals after the use of liposomal lipoflavon, soluble lipoflavon and corvitin in comparison with untreated growths respectively at 1.33, 1.28 and 1.28 times.

Thus, preparations of quercetin had an effect on the parameters of the prooxidant-antioxidant system, reducing not only the activity of the LPO, but also the processes of free radical proteins oxidation against the background of more activation of various parts of the antioxidant system in animals' bodies.

Marchyk F.D., Protsak T.V., Trykur V.S.

EMBRYOGENESIS OF URINARY SYSTEM IN PRENATAL PERIOD OF HUMAN ONTOGENESIS

Higher State Educational Establishment of Ukraine «Bukovinian State Medical University», Chernivtsi M.H. Turkevych Department of human anatomy

After 5 weeks of fetal development observe initial stages of formation of primary germ germs, accompanied by a process of separating it from extraembryonic structures. In this case, the ventral and lateral walls of the body of the embryo are formed. This process is clearly observed both at the level of the cranial and caudal divisions. In the caudal part, the cloacal membrane and the allantois are revealed as the protuberance of the anterior wall of the rectum. Allantois is placed in the direction of the abdominal wall of the embryo, joining with other structures in the area of the future umbilical ring. In the mesoderma of the allantois, anlage the vessels that form the system of the umbilical vessels. In this period, the greatest development reaches the nerve tube, which is the axial (axial) organ of the dorsal part of the embryo. On the histological sections, the dorsal cord has the form of a longitudinal strip from the cell mass placed ventrally in the rudiment of the nerve tube. At the end of the 4th week there are over 38 pairs one. In a further development of the embryo walls there are changes in the shape of the side parts segments, they take the form of plates, consists of two layers: the external and visceral, which are adjacent to ectoderm and endoderm of amniotic cavity and yolk sac cavity with time they formed celom of embryo.

Primary kidneys (mesonephros) are the largest organs of the embryo and extend from the level of the third cervical to the first sacral segments, that is, almost the entire length. The primary kidney in this stage consists of 56 mesonephic glomeruli, separated by layers of condensed mesenchymal cells.. The middle parts of mesonephros are thickened from front direction, cranial and caudal are thinned, resulting in mesonephros are fusiform appearance.

Protsak T.V., Molyn L.R.

THE ROLE OF FOLLOWING ACID AS A PRINT SPINA BIFIDA

M.H. Turkevych Department of human anatomy Higher State Educational Establishment of Ukraine «Bukovinian State Medical University», Chernivtsi

The problem of congenital malformations remains one of the most urgent in modern health care. The main role in the formation of anomalies and defects is not the hereditary nature of the fetal nervous tube, from which the most important structures of the nervous system - the spinal cord and the brain are formed – plays a deficiency of folic acid.

Neural tube defects (NTD) appear as a result of a violation of the closure of the nerve tube. During neurulation, the closure of the nerve tube and the laying of the axial structures of the embryo from the 16th to the 28th day of embryogenesis. Early periods of pregnancy, if it not associated with hereditary factors, are crucial for the formation of defects in the development of the neural tube, and all modern methods for preventing this pathology spread to periods before the pregnancy and its early weeks. The common type of NTD is Spina bifida, which occurs as a result of a combination of genetic factors and risk factors. The clinical types of the defect of the neural tube differ from each other depending on somphet, in which the closure did not happen. The prenatal diagnosis of NTD is carried out by ultrasonography, due to the introduction of biochemical methods, methods of intraoscopic examination of the fetus, depending on the period of gestation. The treatment of Spina bifida depends on the level and degree of lesion, the presence of concomitant anomalies.

Consequently, it is necessary to introduce the prevention of congenital malformations of the development of the neural tube. The effectiveness of this work is possible with the improvement of the medical genetic service, the implementation of international standards in its activities, extensive information work among health workers and the population, taking into account the principles of bioethics and the involvement of civic organizations in this work.

Protsak T.V., Zabrods`ka O.S. Maykan P.O.

SHORT INFORMATION ABOUT CONGENITAL MALFORMATIONS OF THE NERVOUS SYSTEM

M.H. Turkevych Department of human anatomy Higher State Educational Establishment of Ukraine «Bukovinian State Medical University», Chernivtsi

Structural measures aimed at showing that people manifest themselves in a direct and unpopular manner, both folk and natural organs are all natural wadi rozovitku. What matters is the structural causes of invulnerability and mortality in young children.

Spina bifida occulta - often this form is called “latent spina bifida”, since the spinal cord and nerve roots are not damaged, and there is also no defect in the back. This form is characterized by only a small defect or gap in the vertebrae that form the spinal column.

This anomaly occurs on the 3rd week of pregnancy. This is an incomplete closure of the neural tube in full in the existing spinal cord.

Hydrocephalus is a disease characterized by excessive accumulation of cerebrospinal fluid in the ventricular system of the brain as a result of the complication of its movement from the secretion site (the ventricles of the brain) to the place of absorption into the circulatory system. At first, parents may notice that the child often cries, is restless, moody, her chin and upper limbs are shaking while crying or bathing. Together, these symptoms are described as irritability syndrome.

Complete rachishis is a complete defect of the posterior wall of the spinal canal, soft tissues, skin, and meninges. The spinal cord is located in the area of the defect openly and has the appearance of a deformed thin plate. Hernial protrusion is absent.

Chiari's anomaly is a congenital malformation of the nervous system, in which the correct formation of the cerebellum, its placement and relationship to the medulla, cervical spinal cord and closely located bones are impaired. There are four types of Chiari anomaly; most often hydrocephalus occurs with anomalies of the 2nd and 3rd types, much less often with the 1st and 4th types.

Thus, the prognosis in the case of congenital defects of the central nervous system is unfavorable, most of them are incompatible with life. Children often die from the addition of intercurrent infectious diseases.

Babin V., Kushnir A.M., Khodakovska O., Rynzhuk A.

**FEATURES OF MORPHOGENESIS AND OPTIONAL
ANATOMY OF THE LOWER SHEEP IN FAMILY FOODS**

*Higher State Educational Establishment of Ukraine «Bukovinian State
Medical University», Chernivtsi*

The elucidation of the regularities of the sexual and individual variability of human organs and systems in the process of its development is an actual direction of morphological research. Comprehensive knowledge of the peculiarities of the dynamics of changes in the morphometric indices of the mandible in relation to age, sex and constitutional type factor will allow to clearly determine the degree of maturity of the fetus by means of prenatal medical diagnostics, to develop preventive measures and diagnostics of the variants of the structure and congenital malformations of the human maxillofacial area. By means of multivariate regression analysis, we determined the dynamics of changes in the basic morphometric parameters of the mandible in relation to age, sex and constitutional type coefficient. The analysis of the interdependence of the distance between the articular branches of the mandible from gender, age, and constitutional type in human fetuses showed almost the same dynamics of the change in this morphometric index in the fruits of both sexes with the highest and average values of the constitutional type coefficient. However, in female fetuses with the lowest constitutional type (dolichomorphic type), starting from the 6th month of fetal development, accelerated growth rates of the distance between the articular branches of the mandible are present, and the dynamics of the increase of this parameter approaches the rectilinear. Consequently, we can conclude that the distance between the articular branches of the mandible is characterized by extreme forms of anatomical variability (highest rates) in females of Brachymorphic constitutional type. In studying the correlation of the magnitude of the angle of the mandible with sex, age and constitutional type, it has been found that the size of the angle in the male fruit with a decrease in the coefficient of the constipation type is uniformly reduced. However, in the case of fruits with the highest

constitutional type (dolichomorfny type) with increasing age, the angle is reduced. In females with mean and highest constitutional-type indices, the correlation of the mandibular angle and age is similar to that of male, however, in brahymorphic objects with an increase in age from the age of 6 months of fetal development, the angle of the angle tends to rapid rectilinear growth to the end of the prenatal period development. The study of the nature of the interdependence of the maximal length of the mandible from gender, age and constitutional type in human fetus revealed a decrease in this morphometric index in the brains of the brachiopod type, while in females of all constitutional types, its decrease was observed at the 6th month of fetal development with subsequent growth to the end of the fetal development period. It should be noted that female females of the dolichomorph constitutional type have almost straightforward growth rate of the maximal length of the mandible in the fetal period of fetal development. The study of the interdependence of the magnitude of the angle of the body of the mandible from gender, age, and constitutional type allowed the asymmetric sex-age dynamics of changes in this morphometric index to be established. So, if for the fruits of both sexes with average values of the constitutional type the magnitude of the angle during the fetal development period is almost unchanged (in the male, it decreases somewhat for 6-7 months of fetal development, and in the female sex, on the contrary, increases), then at the edges of the constitutional range variability (in brahymorphic and dolichomorphic objects), it is larger in males and less in feminine than mesomorphic types. It was revealed that starting from the 6th month of fetal development, the angle of the mandible in male objects of the dolichomorph constitutional type and in the objects of the female type of dolichomorph constitutional type tends to be straightforward up to the moment of birth. The study of interdependence of the length of the body of the mandible from gender, age, and constitutional type in human fetus has shown a decrease in this morphometric index in the male brachymephic type, and in the females of the females of the dolichomorph constitutional type, it is reduced at the 6th month of fetal development with subsequent increase to the end of the

fetal development period. In the study of the relationship between changes in the thickness of the mandible, age and constitutional type in human fetus, it has been established that this morphometric index in brahyomorphic objects of both sexes tends to slow down the growth rate. It should be noted that this morphometric index in females of all constitutional types decreases during the 6th month of development. Multivariate regression analysis of the correlation of height of the mandible, gender, age and constitutional type in human fetuses showed a weak interdependence of the investigated parameters in the mesomorphic objects of both sexes (except for a slight decrease in the height of the mandible in female fetuses during the 6th month of fetal development). In brahyomorphic female objects, at the end of the 6th month of fetal development, rectilinear growth is observed, and in the male, on the contrary, a decrease in this morphometric index. For dolichomorphic female objects, the achievement of the highest values of the height of the mandible at the 7th month of fetal development is typical, and for males – a decrease in the rate of growth of this indicator in the same period, followed by its stabilization before birth. In the study of the relationship between the changes in the length of the mandible, age and constitutional type in the human fetus, it has been established that this morphometric index in the brahyomorphic objects of both sexes tends to slow down the growth rate, while in dolichomorphic female objects, it is linearly increasing, starting from from the 6th month of development. The interdependence of the volume of the mandible on gender, age and constitutional type in the human fetus is characterized by the highest values of the index in the females of the brahyomorphic constitutional type and the smallest ones - in the fruits of the dolichomorphic male body structure at the end of the fetal period and in the fruits of the brachymorphic female structure of the female 6- 7 months of intrauterine development.

Tkach I., Karavan M.G., Unhurian V., Savchuk R.
THE DEVELOPMENT OF JAWS

Higher State Educational Establishment of Ukraine «Bukovinian State Medical University», Chernivtsi

The study of sources, terms, chronological sequence, variants of structure, critical periods and features of the age-old anatomy of the human zuboschelepny system is an important direction of morphological research, which contributes to solving an important medical and social problem - improving methods of prevention, early diagnosis and effective surgical correction of birth defects and treatment of acquired diseases of the lower jaw of a person.

Wounds of the maxillofacial area occupy the third place among the inborn anomalies, 70% of them constitute inborn non-burning of the upper lip and palate, and 30% - various forms of craniosynostoses and craniofacial dysostoses. The increase in the incidence of acquired and acquired defects in the human tooth-jaw system, in particular the mandible, requires further complex studies on morphogenesis and the peculiarities of spatial-temporal organ transformations in the early period of human ontogenesis.

From the 9th to the 12th weeks of development there are several critical periods of the development of the mandible associated with the formation of the temporomandibular joint, the union of the two parts of the jaw into one, the formation of the end points of attachment of the muscles, and the beginning of regressive changes in the cartilage .

From the 9th to the 12th weeks of development there are several critical periods of the development of the mandible associated with the formation of the temporomandibular joint, the union of the two parts of the jaw into one, the formation of the end points of attachment of the muscles, and the beginning of regressive changes in the cartilage .

During the 9th week of the Meckel, the cartilage passes through the entire lower jaw and is still connected to the auditory ankles [The Meckel's Cartilage in the human embryonic and early fetal periods / Wyganowska-Świątkowska M.]. As soon as most of the muscle fibers move from the cartilage to the lower jaw, it loses contact with the bone and its area of cross-section decreases. In the pectoral department, he experiences osteopenia and becomes an integral part of the mandible, and further vacuolation of cartilage cells occurs. The cooking is thinning and at the

same time there are polyday areas in the center. In the site of the myelophysis, the structure of the cartilage remains unchanged.

At the end of the 12th week cartilage is exerted, mainly on the lower edge. Bone beams in the lower jaw form a furrow that is open towards the oral cavity. In the future, the rudiments of the teeth are closer to her, and the vessels and collateral nerves pass along her bottom [Three-dimensional analysis of mandibular growth and tooth eruption / S. Krarup, T.A. Darwin, P. Larsen]. Gradually, the number of bone beams increases and they form the origin of the spongy substance of the body of the mandible. The gaps are filled with loose connective tissue, vessels and bone marrow [Architecture and mineralization of the developing cortical and trabecular bone of the mandible / L. Mulder, J.H. Koolstra, H.W. de Jonge]. Further growth of the edges of the furrow leads to the formation of the mandibular branch of the mandible [Prenatal formation of the maxillary and mandibular alveolar bone in humans / R. J. Radlanski, H. Renz, U. Kalinke]. During this period, the posterior end of the future mandible connects with the scalar of the temporal bone, forming the temporomandibular joint, which develops an articular disk [Malanchuk V.A. Study of the biomechanics of the mandible on three-dimensional computer models by the finite element method / VA Malanchuk, MG Krischuk, AV Kopchak]. The branches of the jaw in their development are initially cartilaginous stage, and only then they become aspirated.

Growth and weakening of the mandible extends to the period of newborn birth. Almost to the end of the fetal development, it is even and connected by the median line of fibrous cartilage [Madhavan S. Mandibular Development and Its Age Change / Sanjay Madhavan]. Shortly before the birth of the coarse fiber, the bone tissue of the jaw is replaced by the lamellar and the first gurus systems (channels) appear [The skeleton and musculature on the fetal MRI / U. Nemeč, S.F. Nemeč, D. Krakow].

Violation of the morphogenesis of the facial part of the head leads to the appearance of variants of the structure and birth defects of the tooth-jaw system, the lower jaw in particular. There is a median cavity of the mandible which occurs as a result of violation of the growth of mandibular gill arc at the stage of perineal oral cavity formation [Patten B.M. Human

embryology / B.M. Patten – M.: Medgiz]. In addition to this anomaly, defects often occur due to local growth disruption. These anomalies may be insignificant, but they violate the harmony of the face [Shepitko VI New possibilities of computer tomography in anthropometric studies of the skull / VI Shepitko] Among them - microgravity, in which the lower jaw lags in size from other facial structures [Falin L.I. Human embryology / L.I. Falin]

he analysis of scientific literature has shown that despite the large number of scientific works devoted to the study of the structure of the tooth-jaw system, there is a lack of comprehensive research on the development and structure of the mandible, which would cover the entire period of development – from bookmarking to the formation of its definitive structure. Therefore, there is a need to clarify the critical periods of the morphogenesis of the mandible in the dynamics of intrauterine development.

Proniaiev D.V., Laiuk D.I., Kudla M., Harchynska Y.

INJURIES OF THE MAXILLOFACIAL AREA

Higher State educational institution of Ukraine Bukovinian State Medical University, Department of Anatomy, topographic Anatomy and operative surgery

The prevalence of maxillofacial injuries in today's world is connected with the criminalization community, the terrorist threats, the growing number of local military conflicts and civil unrest. Injury of maxillofacial, moreover, arises as a result of accidents on the hunt, at careless and despite the handling of firearms, suicide attempts, etc. For the past 1.5 year in Ukraine is marked by a sharp rise in the number of gunshot wounds during the revolutionary events in January-February 2014, the military action in the East of the country and as a result of the increase in the number of firearms (mostly illegal) at the hands of the people.

Injury of maxillofacial areas occur when shots with all types of firearms, oppositional parliamentary forces ammunition and various explosives and are characterized by significant injuries of tissues and organs, surgical treatment complexity and high risk of complications that

threaten patient and caused his disability . Having first come across this kind of injury in the 14th century, the surgeons explained the special nature of the damage, their hard course of trend towards the development of complications with the presence of specific gases of toxic substances. An admitted method of treating such "poisoned" wounds was to sew hot iron and wounds pouring boiling oil. This incorrect practice was stopped only by the famous French surgeon Ambruaz Paray, who published the first book on the "method of treating wounds caused by firearms in 1545.

So, in the years of the second world war, the share of maxillofacial surgery damage in the structure of health losses was 3.5-5%, during the war in Afghanistan and Chechnya is 8.5-9%. In the conflict in the East of Ukraine, the frequency of lesions of the head and neck is marked at level 39 - 40%, and in the fighting in Palestine and Lebanon, carried out special operations forces of the Israeli army, more than 54 % . Timely, balanced and high-quality provision of surgical care is one of the basic conditions of life and the prevention of serious complications in wounded terms of conducting warfare. Terms of engagement, especially firearms, which are used in the East of Ukraine, radically different from such prominent gun conflicts. The frequency of the gunshot wounds of the head during the Great Patriotic War was 5.2 - 7%, during the warfare of today it is almost 19%.

Therefore, the primary surgical treatment of firearm wounds in the maxillofacial section, what should be the final volume and nature of intervention is seen as a sophisticated operation with deep checkup not only damaged tissues and organs, including the bones of the facial the skull, but also neighboring areas that were hit and shake the great force. The authors indicate that early aggressive surgical tactics with primary reconstruction provides the best aesthetic and functional results, and the level of infectious complications in terms of application of modern antibacterial drugs for remote and immediate recovery after gunshot wounds will probably not differ.

Postevka I., Artysh V., Yuzefovich V., Dutka L.

**INJURIES TO THE UPPER JAW AND RESTORING THE
MUSCLE -BONE SYSTEM AFTER INJURY.**

Higher State educational institution of Ukraine Bukovinian State Medical University, Department of Anatomy, topographic Anatomy and operative surgery

The statistical data indicate that the frequency of damage to the middle third of the bones in the last quarter century has steadily increased, according to MA. Lamberg (1978), annually by 20%. So, according to JOMOS fractures of the bones of the maxillary complex make up 13.8%, and according to statistics from the clinic at the University of Osaka 10.5%. This is supported by high urbanization of the population, growing technical equipment, and the intensification of production, increasing the speed of transport, improving diagnostic methods. Exploring biomechanics maxillofacial trauma, M. A. Nahum (1975) found that for damage the front the walls maxillary sinus required impact force in the 65-78 kg. Bones of the middle zone due to vaulted structure, buttresses alternate with places of weak resistance (front, back, medial walls of the upper jaw, bottom of the ocular fossa). Thus, the model on the one hand provides the intimate connection of bones, but also leads to predictable types of fractures, that in most cases, fractures are comminuted, despite the fact that taking single bone of this type takes place on the first bending cysts and then its destruction. In cases where the force of impact is large and directed perpendicular to the nasofrontal buttress is happening transverse fracture of the body upper the jaw. At the same time, in the area of the nasofrontal buttress, the direction of the fracture is straight, but in the future as a result of depreciation spongy matter, reduction strength action and vector decomposition her fracture lines not directly, but in connection with destruction places weak the resistance will be directed during the alveolar buttress, as a result what occur smashed damage front and side the walls maxillary sinus, such mechanism sagittal and asymmetric bilateral fractures upper the jaw at fractures of the alveolar processes give the existing methods good results, then with suborbital and sub-basal fractures with a large displacement or a tallness of chips in a number of cases it is possible to achieve only the initial bite, and the normal shape of the bell can not be restored always. Residual deformation you can Merge into four groups: 1) consequences damage orbit: phenophthalm, diplopia, violation tearful outflow, traumatic epicanthus and false hyperterolism ; 2) flattening average zone face; 3) dipping nose root,

curvature nasal septum, dacryocystitis; 4) violation of bite. Of infectious complications meet basal meningitis that occurs when the damage occurs sieveplate, lattice bones, osteomyelitis, sinusitis.

Consequently, due to the special placement of the compact and spongy substance, as well as the vaulted structure of the fractures of the maxillary bone in the form of comminuted fractures, fracture of the upper jaw, fractures of the anterior, posterior, medial walls of the upper jaw, the bottom of the ocular fossa, due to the understanding of biomechanical processes in the fracture we can choose the best treatment options

Tovkach Yu.V., Didkivska A.R., Voloshun V.L.

CHARACTERISTICS OF THE FRACTURES OF THE BONES OF THE MAXILLOFACIAL AREA

Higher State educational institution of Ukraine Bukovinian State Medical University, Department of Anatomy, topographic Anatomy and operative surgery

Gunfire fractures are characterized by significant destruction of bone and tissue surrounding it. Gaps are often accompanied by damage to large vessels and nerves. These fractures are mostly multicellular, often causing significant bone defects. Fractures of the bones of the skull are often complicated by damage to the internal organs. Types of displacement of the chips are related to the mechanism of injury and muscle contraction. The number of fractures are single and multiple. To solve the main problems in treating patients with fractures of the maxillofacial area, it is necessary to carry out the following main measures: repositioning - comparing or moving the chips to the correct position; immobilization - fixing the chips in the correct position for the period necessary for their consolidation (consolidation) with the help of conservative and operational methods; drug treatment is aimed at preventing complications during treatment; Physical methods of treatment - to improve tissue trophism and prevent complications. There are two types of regeneration: physiological and reparative. Physiological regeneration refers to the restoration of tissue structures of a healthy organism as they age and die. A clear example of this is the skin - a permanent detachment and removal of the epidermis. Physiological regeneration is a constant and very slow process that does not cause a

stressful situation in the body. Reparative regeneration is the recovery of damaged or lost tissue. The degree and quality of the regenerative process in different tissues are different. The higher the differentiation of the tissue (nervous, muscular), the less it has the ability to restore its structure. Therefore, anatomical repair of the damaged area occurs due to replacement of the defect with the connective tissue - a scar. Damaged bone tissue is able to pass through a number of stages of the reparative process and relate its anatomical form, histological structure and functional suitability.

Tovkach Yu.V., Pavlik A.L., Malyshevsky I., Shumko B
**ATROPHY OF THE BONE TISSUE OF THE JAW IS ITS
RECOVERY**

*Higher State educational institution of Ukraine Bukovinian State
Medical University, Department of Anatomy, topographic Anatomy and
operative surgery*

The bone tissue of any tooth can undergo dystrophic processes. Clinically, it can not manifest itself. In some cases, the presence of an atrophy of the jaw appears with any doctor's interventions conducted directly in the oral cavity.

But there are occasions when young people with the help of which young jaw atrophy becomes noticeable in connection with an early dropout of teeth and their long absence in the mouth. External signs of bone destruction can be pronounced. In patients there are wrinkles in the area of missing teeth, there is a tingling of cheeks. This is because the facial muscles that attach directly to the bones are also exposed to adverse factors in the oral cavity. Many patients complain of difficult chewing food. Some have a tongue change. Often, at the atrophy of the jaw there is an outcrop of the necks and distortion of the remaining teeth, which, in turn, can lead to the development of severe periodontal disease.

You can restore the required bone tissue both upper and lower jaw in various ways. For these purposes, specific preparations of phosphorus and calcium can be used, as well as specially prepared and prepared bones of some animals or their own resources. In this case, bone tissue in most cases is taken from the area of the chin of the patient, where after some time the

most complete regeneration of the structure of the jaw bone occurs. The new bone is formed within six months after the performed osteoplasty. Despite the length of the process, osteoplasty is popular among patients due to the small number of side effects and its high performance.

Marchyk I.V., Protsyuk D.I., Staroverskaya O.O., Staroversky A.V.
**MINIMAL INVASIVE TECHNIQUES OF PREPARATION
(TUNNEL PREPARATION, SLOT-MAKING, BATE CAVE-
MAKING, ART-TECHNIQUE)**

Higher state educational institution of Ukraine bukovinian state medical university, department of anatomy, topographic anatomy and operative surgery

Caries of teeth is a disease that can affect everyone. The traditional method of treatment of caries is the use of boron, by which the process of elimination of caries affected tooth tissues is carried out in order to prepare the carious cavity for sealing. Unfortunately, the treatment process is often associated with pain. The decoration of the teeth affected by caries using boron has been used for about 100 years. During this long time only one changed - the speed of rotation of the boron has increased. Although the need for caries treatment is less painful, a more effective method that prevents excessive doctor's intervention in healthy tissues, it is very relevant. The concept of minimally invasive treatment is a preventive concept focused on maintaining dental health of the patient and reducing the need for invasive treatments (preparation and sealing). Another direction of development of minimally invasive methods of filling the carious cavities is ART-technique (atraumatic restorative treatment - atraumatic restorative treatment). The carious cavity is cleaned by an excavator, without the preparation by means of a drill. Then it is dried and sealed with glass ionomer cement - a material that is easy to use and has anti-cariogenic effects. The tunneling method is the most accurate and most widespread method of preparation. Here a turbine unit with a speed regulator is used, diamond or metal tips. The disadvantage of the tunneling

method is the heating of the enamel, the possibility of damage to soft tissues or the appearance of microcracks with the use of low-quality equipment. Bate-cave, translated from English, is a bay cave, a volumetric cavity with a narrow entrance. This method of minimally invasive intervention is used on occlusal surfaces, usually molars, with medium and large carious lesions that propagate under the hills. The peculiarity of the bate-cave-decoration is that the entrance to the center of the carious defect is formed by a spherical boron of medium or large size, and then circular motions are carefully removed struck dentin and underneath the intact surface is hung with enamel. The method is quite complicated in technical execution, it requires special precision and adherence to the rules of safe preparation of hard tooth tissues. With proper preparation of the carious cavity and adequate sealing, the risk of cutting the hanging edges of the enamel is minimal.

Slot translated from English - slot, channel, slit. This method of minimally invasive intervention is used on the contact surfaces of molars and premolars for small and medium carious lesions that are localized below the equator or at its level. Today, slot preparation is considered more justified by the treatment of small and medium grade cavity defects of Grade II for Blacks than the traditional preparation of the regional crest for access to the carious cavity.

On the basis of elaborated articles, reports, information from the Internet, you can make the following: Minimally invasive techniques represent a perfect system of approach to the problem of caries and give the opportunity to complement and continuously improve the methods of treatment.

Maxymiv O., Stolets A., Yakovec K.

HEALTHY LIFESTYLE IN THE PRESENT

Higher State educational institution of Ukraine Bukovinian State Medical University, Department of Anatomy, topographic Anatomy and operative surgery

At the present stage of development of society, the priority direction of the educational process is the formation of moral values in children and pupils of youth, which has made civilization for millenia of its existence.

Young people are extremely illiterate in the issue of healthy lifestyles. Drug addiction, smoking, alcohol use, substance abuse - this is often seen as a better leisure activity among a certain part of boys and girls.

Support for young people in healthcare, prevention of asocial phenomena, and the formation of a healthy lifestyle is a system for strengthening the health of young people, shaping the need for young people in a healthy lifestyle.

The above problems exist in Ukrainian society not the first year. Ukrainian youth of the 21st century socialized in an independent democratic state - it is more independent, independent, uncompromising. She has the ability to independently solve their problems. At the same time, society, like many years ago, tries to take care of the youth and to impose its ways of solving the problems of the youth environment.

Work on the formation of a healthy lifestyle should be conducted in accordance with the conditions that dictate our present. And for this purpose it is expedient to study, rethink and rebuild various sections of cultural and educational work, to introduce domestic innovative ideas, world experience. And most of this work falls on the teachers of teachers of physical education.

Taking into account the foregoing, it becomes clear that there is an urgent need to create a comprehensive model aimed at improving the health of children and young people in Ukraine and that such a model should be based on the principles and principles of the theory and practice of the formation of a healthy lifestyle recognized by the world community.

As the world experience shows, the lifestyle that children and young people are leading is a major contributor to health. And the prospect of improving public health is most closely related to the systemic activities for the formation of a healthy lifestyle. The formation of a healthy lifestyle is a much more effective and cost-effective strategy than a continuous

increase in the cost of treating the effects of an unhealthy lifestyle that does not provide the desired result.

This situation can be improved by applying a new approach to healthy lifestyles, based on a modern health-care approach, which takes into account all aspects of it.

And according to Lozovytsky's study of a healthy way of life should be systemic and should contribute to the harmonious development of psychophysical abilities of youth. It is not limited to a periodic focus on the realization of a healthy lifestyle as a collective value.

Therefore, it should be borne in mind that any work on promoting a healthy lifestyle is aimed at solving an important task, the main purpose of which is to preserve the future of the nation!

Andriyets M.M., Kyzuk F.V., Smoliak I., Buhaj I., Kozak M., Kozak Y.

HEALTHY LIFESTYLE STUDENT YOUTH

Higher State educational institution of Ukraine Bukovinian State Medical University, Department of Anatomy, topographic Anatomy and operative surgery

Caring for your own health is a very topical problem in today's society, because health is considered to be the main social value. However, not all people are well informed about a healthy lifestyle, and some are deliberately neglected by them. Keeping a healthy lifestyle is important for every person, and in the first place - for student youth.

Physical culture is the key to a healthy lifestyle. Strengthening and maintaining health is a priority area of the main legislative acts and normative legal documents on physical culture. It is also worth paying attention to the fact that students are always in a stressful state, because mental activity is associated with emotional stress, especially during the session.

Physical culture and a healthy lifestyle can reduce the risk of poor health or illness to a minimum, and sometimes to zero. A healthy lifestyle is closely intertwined with physical education, as stated in the national doctrine of educational development. Healthy lifestyle is a way of life based on the principles of rational organization, activity, work, tempering

and protecting against adverse environmental effects and allowing for deep old age to maintain ethical, mental and physical health.

A healthy lifestyle requires compliance with the following guidelines:

- familiarization with scientific and medical literature on these issues;
- alternation of work and rest;
- abandoning bad habits;
- independent study of sports and physical culture;
- observance of the regime of day and motor regime;
- use of various means of physical education, sports and tourism in everyday life;
- stay for some time in the fresh air.

Physical culture plays a leading role in maintaining a healthy lifestyle. For normal functioning of the student's body, a certain amount of motor activity is required, which is embodied in physical exercises. Regular physical activity leads the body to a state of *trenirovannost*, which is based on the process of adaptation, that is, the adaptation of the functions of different organs to the new conditions of their activities. Numerous studies show the beneficial effects of regular physical exercise on the health and physical condition of a person of any age. At different ages, these classes have different goals. In student's classes, classes are especially important: they are aimed at improving physical fitness, physical development and physical performance, and preventing diseases that may occur at an older age. But by themselves, they do not bring the desired changes in the health of a young person.

Only in conjunction with other these guidelines can contribute to the overall healthy lifestyle and well-being of the student.

Take care of your health and, consequently, your well-being!

Andriyets M., Andriyets V., Ungyrian A.

SPORT IN HUMAN LIFE

Higher State educational institution of Ukraine Bukovinian State Medical University, Department of Anatomy, topographic Anatomy and operative surgery

Life and longevity are inextricably linked to health, which is influenced by many factors. Sport (or lack thereof) is one of them. Sport and human health are inseparable from one another. Sport has a good

effect on the whole body, including on the psyche: during physical activity, a person feels "muscular joy" through the release of the corresponding hormones in the blood.

Sports and health of man from ancient times are the subject of many scientific discussions. He unites people, acquaints them among themselves, sports strengthens the health, character and even the mental abilities of people who engage in them, develops in them such skills as speed, agility, reaction, coordination, endurance, patience and strength. Sport makes people more resistant to negative environmental factors.

However, each person has a proper attitude to the sport: someone prefers to watch him on TV, someone prefers to just do some kind of sport or general physical training, but for someone sport is a means of subsistence. The latter include active athletes, trainers, doctors, directors of various sports associations, sports fans, and others. And each of them contributes to the development of sport on our planet.

The impact of sport on human health is enormous. However, sports are not only health. Any physical activity is also required for the activity of thinking. Famous ancient scholars and philosophers considered exercise to be the best rest for the mind. In particular, it is definitely known that some mathematicians, if they could not solve a problem, left him and walked for a walk. And during these walks, the answer itself came to their head, and they did not think about it at all.

In a word, without sports, it is impossible to have good health, and without health, life is impossible. Perhaps only survival. Accordingly, the role of sport in human life is the most important attribute in the way of life of people who are looking for health and want to preserve their beauty and attractiveness of the body for many years. The result of long-term sports is not only a slim and beautiful figure, but also enormous health.

And even sports make you feel the joy of your own achievements. It did not happen to you at one time and roll the ball through the grid, and now - you take prize places in the competitions! And you understand the price of the hard work and work on yourself. And besides, you realize that perseverance helps you to achieve any goals.

It's not necessary to be a professional athlete to enjoy and enjoy sports. Many people run, someone is walking on aerobics and fitness, someone playing football or doing karate. The main thing is to like it. At

the same time, it makes you physically strong and self-confident, and also gives you the opportunity to get to know many interesting people.

Shkvarkovskaya N., Shkvarkovsky I, Shvab A., Cherney A.

TREATMENT OF FRACTURES OF LONG BONES

Higher State educational institution of Ukraine Bukovinian State Medical University, Department of Anatomy, topographic Anatomy and operative surgery

In Ukraine and abroad there is an increase in the number of victims with closed and open fractures of the limb bones. On its own, this is due to an increase in the pace of life, and the mechanization of processes that occur in the conditions of scientific and technological progress. In the mechanism of femoral injury, predominantly high energy agents, such as the effects of an accident, fall from a height. Fractures of long tubular bones occur quite often and represent serious damage to the articular parts of the musculoskeletal system. These bones are the largest in the skeleton and strongest in power and axial load. Among all injuries to the bones of the skeleton, traumas of long tubular bones make up from 48% to 80%. In this case, the fractures of the lower extremities occur twice as much as the upper extremities. In recent years traumatology has been replenished with new, more advanced and effective methods of treating injuries in the locomotor system. In the publications of domestic and foreign authors described a large variety of methods and ways to treat fractures of the distal tibia - from plaster casts, orthoses and skeletal traction to different types of open and closed osteosynthesis. The main attention is paid to the classification of fractures, depending on the displacement of fragments, as well as the choice of tactics of surgical treatment.

All this led to increased interest in the problems raised, the dynamic development of diagnostic methods, establishing mechanisms of fractures and their treatment.

Tovkach Yu.V., Vepriuk Yu.M., Shulgina V., Klantuyk Y.M.,

**CRITICAL STAGES OF MAXILLA ONTOGENESIS
DEVELOPMENT IN FETUS**

*Higher State Educational Establishment of Ukraine
“Bukovinian State Medical University”*

The proposed work describes the necessity of studying and establishing the anatomical features of the upper jaw, disorders and reactivated displacement

in the system of extra-intraorganic vascular bed and the efferent innervation of the muscles of the newborn jawbone apparatus.

During the 6th-7th week of embryogenesis, a hard and soft palate is formed and the primary oral cavity is divided into two sections – the secondary oral and nasal cavities. The palatine processes are formed on the inner surface of the maxillary processes, the edges of which are first inclined downwards and are located near the bottom of the oral cavity on both sides of the tongue. Due to the growth of palatal processes, a large portion of the hard palate is formed. The anterior part of the hard palate is formed due to the growth of the palatine processes with the incisor part of the upper jaw. The septum, which arises as a result of the described processes, is the rudiment of a hard and soft palate, and it separates the secondary oral cavity from the nasal cavity.

With insufficient development and non-growth of the palatine processes splitting of the hard and soft palate (palatoschisis), the so-called cleft palate (rictus lupinus) occurs.

Sometimes splitting is formed only in the soft palate. The deformities of the maxillofacial area, in addition to aesthetic defects, cause respiratory and nutritional disorders in young children. During the 7th week of embryogenesis, along the upper and lower edges of the oral fossa, the proliferation of the epithelium begins with gradual growth in the form of a plate in the surrounding mesenchyma.

Under this condition, a vestibular plate (lamina vestibularis), is formed, on the edge of which a cleft is formed that separates the rudiment of the upper or lower jaw from the corresponding lips or cheeks. This cleft gives the rise to the formation of the oral cavity vestibule. At first the mouth of the embryo is very wide and reaches the angles of the rudiments of the outer ear. Subsequently, due to the growth of the cavity edges and the formation of cheeks, the oral cleft is significantly reduced in size.

Vakarchuk A., Bocharov A.V., Mendel A.O., Tovkach Yu.V.
**PECULIAR FEATURES OF ESOPHAGUS ULTRASOUND
ANATOMY AND THE GASTRIC TRANSITION IN CHILDREN**
*Higher State Educational Establishment of Ukraine
“Bukovinian State Medical University”*

The incidence of diseases associated with the locomotor functional disorders of the esophageal sphincter has been increased dramatically nowadays. The results of the anatomical structure of the oesophageal

gastric sphincter in newborns and children may indicate a possibility of developing Gastroesophageal reflux disease (GRD).

The part of the oesophagus abdominal section is visualized during an ultrasound examination of the abdominal region, both in transverse and longitudinal scanning.

The resulting image is presented on the monitor screen or on a paper in the form of bright spots.

The bright white colour means the reflected echo of the abdominal part of the oesophagus or the upper part of the stomach fundus, which is above His angle opposite the corresponding lateral part of the abdominal part of the oesophagus, and the black colour means the absence of a reflected signal giving parenchymal organs and fluid.

During the study, with cross-scanning in newborns and infants, it was observed that in horizontal sections of the oesophageal-gastric junction at the site in the place where the oesophagus falls into the stomach, the oesophagus was at a certain distance from the fundus of the stomach or the fundus of the stomach was not visualized at all.

When the transverse scanning is being done, the abdominal part of the oesophagus is visualized in the form of a rounded structure with a hyperhegogenic centre - the mucous membrane of the oesophagus, thin hypoechoic - submucose, thin outer hyperechoic layer is a reflection of adventitia of the abdominal part of the oesophagus.

So, while conducting ultrasonographic research of the esophagus, it was found out that that in horizontal sections of the esophageal-gastric junction at the place where the esophagus enters the stomach, it (esophagus) is located at a certain distance from the stomach fundus.

In other cases, the fundus of the stomach was not visualized, or only a small part of the stomach was visualized. The distance from the stomach fundus to the esophagus indicates the size of the His angle and the possibility of infiltration of GRD in the newborns.

Kashperuk-Karpiuk I.S., Vepriuk Yu.M., Holubiak Y., Holban V

TUMOROUS AFFECTIONS OF THE OVARIES

Higher State Educational Establishment of Ukraine

“Bukovinian State Medical University”

For the last years in the whole world has been stated an increasing of tumor frequency and tumorous affections of the ovaries, what has negative effect on reproductive function of this contingent of patients Goyda N. G., Zaporozhan V. N.. Among the benign tumors allocated special group (The WHO classification 1997)-tumorous affections of the ovaries. Between true tumors and tumorous affections there is only external similarity, however their pathomorphological essence is deeply different Serov S. F.

To tumorous ovarian affections of belongs following illnesses: follicular cysts, yellow body cysts, endometrial cysts, paraovarial cysts, General changes of the ovaries. The severity of ovarian tumor's differential diagnosis with tumor-like formations associated with absence clinically expressed differences and unexplained etiopathogenesis of their appearance Kulacov V.I.. In the pathogenesis of central and peripheral functional failures of the system units hypothalamic-pituitary-ovarian significant role is taken by disorders of hormonal function of above listed organs, what usually is the general inflammatory proces's consequence. Frequent development of ovarian tumor-like lesions on the high indexes's background infectious diseases of bacteria's and viral's etiology experienced in puberty, inflammatory diseases of genitalia, complicated childbirth and abortions.

The given data indicates about many unexplained questions, connected with etiology and pathogenesis of ovarian malignant tumors, depends on many of factors, including the applied scheme of patients treatment, the cytostatics mechanism of action, their toxicity, and from the resistance of tumor cells to.

Boiko V.V., Zamiatin P.N., Kizuma P.

TREATMENT OF HYPERESTHESIA OF HARD TISSUES OF TEETH

Kharkiv National Medical University, Kharkiv

At the second stage there is a sensitivity to chemical stimuli - sour, sweet, salty food. And the third stage is marked by painful sensations with mechanical influence - pressing, chewing food. At the first stage, the sensitivity is shown only on the temperature - hot or cold food, cold air. The most diverse is the etiology of this pathology. We are based on the clinical classification Yu.A. Fedorov, according to which, hyperesthesia of dentin by origin is divided into 2 groups:

1. Hyperesthesia of dentin associated with loss of hard tissue of the tooth.

2. Hyperesthesia of dentin, not related to the loss of hard tissues of the tooth.

There is also a classification of defects with hypersensitivity of hard tissues of teeth Yu. A. Agafov and G. I. Ron. They showed a connection of hyperesthesia with various forms of defects in the hard tissues of the tooth. As a result of loss or thinning of the enamel, the tooth is more easily exposed to chemical or mechanical stimuli, namely, the level of the lubricated layer of dentin decreases and the entrances to the dentinal tubule are opened.

Normally, these tubules are hermetically sealed and contain an intercellular fluid that is easily displaced by air, high temperature, cold, and tip of the probe. This rapid, directed inward or outward movement of the fluid in the tubules leads to a change in pressure in the dentin and, in the end, increases the activity of the nerve endings in the pulp or in the dentinal tubules. And the bigger the defect, the greater the sensitivity.

In their classification, the authors divided the defects that appeared on the surface of the tooth as a result of the loss of solid tissue to small defects visible to the naked eye or with the help of optics - microdefects and defects of massive - macrodefects.

The main purpose of treatment of hypersensitivity of a tooth is obturation of dentinal tubules with the elimination of a defect of solid tissues.

In the presence of microdefects adhesives for enamel and dentin, dual-action dispensers, fluorine-containing gels, varnishes and rinses, as well as sensitive paste are used. Adhesives for enamel and dentin increase the bond strength of seals, dentin and heterogeneous sealing materials. Reducing the dentin sensitivity during adhesive application is due to the sealing closure of the dentinal tubules with the zone formed by the components of the adhesive system.

As a dual-action desensitizer, a denture-embedding liquid is used. This solution forms a precipitate consisting of submicroscopic crystals of calcium fluoride, silicon oxide, magnesium and copper. It is believed that precipitated chemical compounds block dentin spaces and eliminate the adverse effects of environmental factors on sensitive tissue. The use of fluoride-based varnishes consisted in applying a film-forming substance to fluorine organic solvents. After drying the varnishes on the surface of the dentin, a solid, brilliant coating that contains the compounds of calcium and fluoride is formed. These compounds protect the surface of dentin from aggressive agents.

Treatment of microdefects can be done, both at the reception at the dentist, and at home. For this purpose, using sensory paste containing fluorine, calcium nitrate, and the like. Fluoride-based rinsers are used to enhance the effect.

Thus, the division of defects of solid tissues of the surface of the teeth into massive (macrodefects) and small, visible with the naked eye or using dandruff (microdefects), minimizes the error in treatment and increases its reliability.

In the treatment of hyperesthesia, due to the presence of microdefects on the surface of the tooth, it is effective to use the tools that wrap the dentinal tubules and stimulate the processes of mineralization of dentin in the complex with anti-sensory toothpastes

Tovkach Yu.V., Kobyalko A.D., Yakovets K.I.

ANTI-REFLUX SURGICAL APPROACH

Higher State Educational Establishment of Ukraine "Bukovinian State Medical University", Chernivtsi

Esophageal cancer is one of the most common forms of the malignant neoplasms of the digestive tract. The middle part of the esophagus is involved more often (50-60%), the lower part - (25-30%). The failure of the esophageal sphincter is a major cause of the rapid increase in the incidence of esophageal cancer. The main manifestation of the failure of the esophageal sphincter is gastroesophageal reflux disease, which in its turn, is complicated by strictures, adenocarcinomas of the esophagus-gastric transition.

Some authors believe that an anti-reflux operation with a variable angle of esophageal lapse into the stomach and a partial fundoplication of the lower esophagus contributes to better remote results than Nissen's operation (V.V. Sumin et al.). In cancer of the lower third of the esophagus, subtotal resection of the proximal part of the stomach and the lower third of the esophagus with the formation of intra-pleural anastomosis is recommended.

Nissen's fundoplication, along with its benefits, can lead to a variety of complications in the post-operative period. Necrosis of the wall of the gastric fundus, which is used for plastics, with subsequent formation of the gastric fistula, is referred to early complications. Similar complications include cardiac hyperfunction syndrome, described by Willaheger. Clinically, it is manifested as a feeling of pressure and pain in the subscapular region, especially after eating. On radiographs, an increase in the gas bubble of the stomach is found, which, not rarely (10-20%), compresses the portion of the esophagus, wrapped up in a stomach cuff. If the distal department of the esophagus and gastric fundus "slip" in relation to the intact cuff, phenomenon of "telescope" occurs as a result of the eruption of sutures on the esophagus at fundoplication.

The consequence of the Laterjet nerve injury during the mobilization of the cardiac part of the stomach is a symptom of gastric denervation. Ulcers of the stomach (2.2%), hernia of the esophagus of the diaphragm (3.7%) are included to the late complications of fundoplications.

Vepruk Yu.M., Uzintskui E.S.

DEVELOPMENT OF TONGUE IN HUMAN ONTOGENESIS

*Higher State Educational Establishment of Ukraine
“Bukovinian State Medical University”*

The formation of the anterior part of the tongue appears for the first time at the 4th week of embryogenesis in the form of two lateral tongue elevations and one medial elevation (odd tubercle) originating from the first throat arch of the embryo.

The primordium of the tongue's back is the second medial tubercle called sublingual elevation, or the bow {copula} that comes from the IInd and the IIIrd throat arches. It should be remembered that the rudiments of the anterior part of the tongue are covered by the ectodermal epithelium of the bottom of the oral fossa, whereas the rudiment of the back of the tongue covers the endodermal epithelium of the anterior intestine of the embryo. With the growth of lateral tongue elevation, an unpaired tubercle overgrowth and together with it forms the front 2/3, or the body of the tongue. The space between the unpaired tubercle and sublingual elevations turns into a marginal groove. The vast majority of muscle fibres of the tongue are formed from myoblasts, which originate from occipital somites.

In the case of growth disturbances of the lateral lingual tubercles, a bifurcated tongue is formed {lingua bifida}. In the case of improper development of an unpaired tubercle, a bifid tongue is formed {lingua duplex}, in the case of a short frenulum, a tongue-tie occurs or {ankyloglossia}. In addition to the mentioned developmental defects, there is also a complete lack of tongue or {aglossia}, underdeveloped tongue {hypoplasia linguae} and a too big tongue (macroglossia).

Caudal to the unpaired tubercle from the bottom of the oral fossa in the direction of the tracheal bud, an epithelial diverticulum grows – the thyroglossal duct, which is the source of thyroid development.

The end of this duct, reaching the end of the 7th week of embryogenesis of its final position in front of the trachea, will turn into a rudiment of thyroid gland. The blind tongue of an adult is the remnant of the embryonic thyroglossal duct. At the 8-9th week of embryogenesis, the formation of the papillae of the tongue begins. The development of taste

buds runs in parallel with the growth of nerve fibres in the epithelium of the tongue.

Differentiation of the buds cellular elements begins simultaneously with the appearance of clusters of non-myelinous nerve fibers directly under the placement of the future taste bud.

During the 9th week of embryogenesis from the IInd pair of pharyngeal pockets palatine tonsils begin to form. The formation of pharyngeal tonsil occurs during the 4th month, and the formation of lingual tonsil occurs during the 5th month of embryogenesis.

Tsurkan I.M., Shumko B.I., Romaniuk H
**THE ACUTE CORONARY SYNDROME
AS A MANIFESTATION OF THE ISCHEMIC HEART
DISEASE**

*Higher State Educational Establishment of Ukraine "Bukovinian State
Medical University" Chernivtsi, Ukraine*

Department of Anatomy, Topographic Anatomy and Operative Surgery

The diseases of a cardiovascular system are called "the epidemic of the twentieth century" which is rapidly spreading nowadays. The ischemic heart disease is one of the most common cardiovascular diseases characterized by high mortality rates. Every year more than 7 million people die because of this disease which comprises 12.8% of all the lethal cases. Every sixth man and every seventh woman in Europe die from myocardial infarction.

A period of intensification of the ischemic heart disease is called the acute coronary syndrome. The term of "the acute coronary syndrome" was introduced in 1996 by a New Zealand Clinician Harvey Wyatt in order to indicate the difficulties in diagnosing and predicting the course of the acute myocardial ischemia which is a threat to the patient's life.

The acute coronary syndrome is a clinically-electrocardiographic symptomatic complex which develops with the acute mismatch of the needs of myocardium in oxygen and its supply due to a thrombotic obstruction (up to 95% of cases), or a persistent spasm (up to 5% of cases) of a coronary artery. The symptoms that indicate a patient's development of either the unstable angina or myocardial infarction in the combination with changes in ECG in the form of a ST segment elevation or without a

ST segment elevation definitely characterize the acute coronary syndrome.

The periods of intensification of the ischemic heart disease are characterized by a relatively rapid formation of a so-called "complicated" plaque in the violation of the integrity of its fibrous membrane formation at the site of a damage of a vessel lumen of a blood clot. Depending on the speed of the formation and the size of a blood clot, the terms of its existence in the lumen of the vessel, the degree of a restriction of coronary bleeding, the state of the severity of collateral bleeding and other factors, the clinical exacerbation of the coronary heart disease is manifested in the unstable angina, the development of myocardial infarction with a Q wave and without a Q wave, a sudden cardiac death.

It should be mentioned that the majority of patients which have been diagnosed with "the acute coronary syndrome with a ST segment elevation", have a further Q-infarction of the myocardium, rarely - non-myocardial infarction, in some cases – the unstable angina. The opposite results are observed in "the acute coronary syndrome without the elevation of a ST segment ", namely, the most characteristic diagnosis is the unstable angina, rarely - non-myocardial infarction and sometimes - Q-myocardial infarction.

The clinical criteria for the unstable angina are prolonged (for more than 20 min) anginaic pain; angina no less than III FC (according to the classification of the Canadian association of cardiologists, 1976) which arose for the first time (during the previous 28 days); progressive angina is no less than III FC; with angina which arose after MI. The typical clinical symptoms of the acute coronary syndrome are the feeling of compression, severity behind the chest with irradiation in the left arm, a neck or a jaw that lasts for several minutes and accompanied by sweating, nausea, abdominal pain, shortness of breath and fainting. Sometimes such atypical manifestations as epigastric pain, dyspepsia and others are observed. These atypical complaints are more likely to be observed in the patients who are over 75, in the women and patients with diabetes, chronic renal failure or dementia.

Consequently, the basis of all the above mentioned clinical manifestations of the exacerbation of the ischemic heart disease is a unique pathomorphological mechanism of the acute coronary heart

disease. In this connection, in recent years various clinical signs of exacerbation of the ischemic heart disease have been united in one concept of "the acute coronary syndrome."

Vlasova K.V., Bulyk R.Ye., Davydenko I.C., Smetaniuk O.V.,
Yosypenko V.R.

**DIURNAL VARIATIONS OF CYTOMETRIC PARAMETERS
OF HYPOTALAMIC SUPRAOPTIC NUCLEUS NEUROCYTES
IN RATS UNDER STRESS CONDITIONS**

Higher State Educational Establishment of Ukraine

"Bukovinian State Medical University"

Department of Medical Biology and Genetics

Chernivtsi

Among the structures involved in the neuroendocrine response to stress, the hypothalamic supraoptic nucleus (SON) became the focal point. The cytometric fluctuations of the neuron parameters of the hypothalamic supraoptic nucleus of rats at different diurnal periods under conditions of immobilization stress remain poorly known.

Experiments are performed on adult male white rats, divided into two series. Immobilization stress is modeled by holding experimental animals for 3 hours in laboratory small cases. The average volume of the neurocyte and its nucleus, the nuclear-cytoplasmic coefficient, the optical density of the cytoplasm stain and the standard deviation of the color of the nucleus of the neurocyte are defined.

A cytometric study of neurons under stress conditions allows us to establish a tendency to increase the volume of the nuclei of nerve cells at 2 a.m. compared to 2 p.m. By measuring the volume of neurons, it is found that the average value of the indicator at 2 a.m. is significantly higher compared to that at p.m. (948 ± 10.4 and 906 ± 10.0 , $p = 0.016$). There is a significant increase in the standard deviation of the color of the neuronal nucleus at 2 a.m. compared to the daily index (8.4 ± 0.13 and 8.0 ± 0.11 , $p = 0.041$). At night, a significant decrease in the nuclear-cytoplasmic coefficient is detected as compared to 2 p.m. (0.260 ± 0.0021 and 0.272 ± 0.0023 , respectively, $p = 0.008$). A decrease in the optical density of the

cytoplasm staining of neurons in the SON at 2 a.m. compared to 2 p.m. (from 0.304 ± 0.0026 to 0.323 ± 0.0027 $p = 0.003$) has been proven.

Under the action of immobilization stress, an increase in the volume of the hypothalamic SON neurons and the standard deviation of the color intensity of their nucleus at 2 a.m. is detected, as compared to 2 p.m. At the same time, there is a decrease in the nuclear cytoplasmic coefficient and optical density of cytoplasm staining of the studied neurons at 2 a.m. compared to 2 p.m.

Yasynskiy M.M., Ozhogan Z.R., Belikov O.B.

**RESULTS OF THE STUDY ON THE TAXONOMIC
COMPOSITION OF THE GUM MUCUS SURFACE
MICROBIOTA IN PATIENTS WITH PARTIAL LOSS OF TEETH**

Higher State Educational Establishment of Ukraine

“Bukovinian State Medical University”

Department of prosthetic dentistry

Chernivtsi

In patients with partial loss of teeth, the listed ecological indices, *S.aureus* is often found and is the leading causative agent of the inflammatory process. Infrequent are *S.epidermis*, *S.hemolyticus*, *S.pyogenus*, *E. coli*, *Acinetobacter* spp., *B. sattaralis*, *N. flavescens*, *M.lacunata* and *C. albicans*.

In 47 patients, 26 strains of microorganisms belonging to 16 different taxonomic groups have been isolated and identified, which, according to the Margaleff species richness index and the Whittaker species diversity index, testifies to the fact that in the biotope, after partial loss of teeth, spatial, nutritional and other conditions are created for development of microbiota in associative groups. It was shown that on gum mucosa in most patients (78.72%) with partial loss of teeth, there persist microorganisms' associations consisting of 2, 3, and 4 microorganism species belonging to different taxonomic groups. Therefore, associations of opportunistic microorganisms having a variety of species interrelations cause the inflammatory processes on the gum mucous membrane in

patients with partial loss of teeth.

It was observed that only in 10 patients with partial loss of teeth (8,51%) monoculture was detected on the gum mucosa, more frequently it was the monoculture of *S. pyogenes*. In most patients, associations consisting of 2 taxons were revealed. Associations of *S. aureus* and *N. lacunata*; *S. hemolyticus* and *B. Catarrhalis*, association of *S. epidermidis* and *C.albicans* was detected in five (10.64%) patients. Other associations, consisting of 2, 3 and 4 taxons, were observed significantly less frequently.

It is known that in each microbes association of a certain taxon in the biotope, the best spatial and nutrient conditions for their existence, growth and reproduction are created. Individual microorganisms of this biotope have the advantage of growing and reproduction and reach a high population level, becoming the leading agents (factors) of the pathological process in the biotope.

It was established that the highest population level in the gum mucosa secretion of patients with partial secondary loss of teeth was found in *S. pyogenes*. Somewhat lower level was observed in staphylococci, colibacilli, acinetobacteria, branhamella, and others.

In patients with partial tooth loss the population level of *S. pyogenes* on the mucosa grows by 2.2 times, *B. catarrhalis* – by 97.67%, *Actinobacter* – by 94.94%, *S. hemolyticus* – by 61.11%, *E. Coli* – 59.70%, *E. cloacae* – 59.33%, *S. epidermidis* – 49.35%, *K. pneumoniae* - 43.0%, *N. flavescens* – 25.60%, *M. lacunata* – by 20.46%. Microorganisms contaminating the surface of the prosthetic bed mucous membrane – *S. aureus* and *C. albicans* – reach the high population level, *S. salivarius* grows by 61.13%, *S. mitris* – by 33.58%, *S. mutans* – by 18.10%, *S. sanguis* – by 14,67%.

Zhyrulyk Y.M., Chernovska N.V.
**DOUBLE PRION AS A PATHOGEN OF ALZHEIMER'S
DISEASE**

*Higher State Educational Establishment of Ukraine
"Bukovinian State Medical University"
Department of Medical Biology and Genetics
Chernivtsi*

The discovery of prions belongs to the American scientist Stanley Prusiner who was awarded The Nobel prize for the "pioneer discovery of the entirely new genre of disease-causing agents and the elucidation of the underlying principles of their mode of action".

Prions are proteins with infectious properties? That cause incurable diseases of humans and animals. Prion disease are caused by formation of the pathogenic form of prion protein, that in spite of physiological form is hydrophobic and has the changed secondary structure. Normally prions are concentrated on the membranes of mainly nervous cells and neuroglia. Prions are considered to take part in creation of synaptic contacts, based on their higher number in the places of neural pathways.

Prion infections belong to lethal neurodegenerative diseases of mammals. After a neuron death the cavities in nervous tissue start to appear, and it looks like sponge. The nature of prion diseases can be hereditary (in the case of occasion mutations of a special section of the 21st chromosome, that is responsible for synthesis of normal prion), sporadic (acquired) in the case of eating the meat of infected animals and iatrogenic via surgical manipulations.

Alzheimer's disease is also an neurodegenerative disease, that is characterized with memory disorders, psychomotoric and lingual functions and leads to inability to be serviced independently and total dementia. There is the accumulation of β -amyloid, tau-protein, and cholinergic deficit, inflammation of nervous system and neurodegeneration.

The scientists of The UC San Francisco were able to identify specific prion forms of β -amyloid and tau-proteins in the brain tissue samples of the 75 patients with Alzheimer's disease with the help of new laboratory tests. Stanley Prusiner, the study's senior author, is convinced, the cause of Alzheimer's disease is double prion, which consists of the prion forms of β -amyloid and tau-protein, that destroy the brain.

Discussing Alzheimer's disease from the point of its prion origin, it would be right to think over the possibility of its transferability via sporadic and iatrogenic ways. Thinking globally, we should talk about the possibility of use prions in bioweapon by volatile countries, that unfortunately would be quite effective, because the lethality of prion diseases is 100%, and there is no cure against the diseases. It is important to remember mad cow disease, that was passed on to cattle via alimentary (sporadic) transmission with food, in which powder made of nervous tissue of diseased animals was added. Anyway it's time to find out any positive use of prions.

Chokan V.I., Zakharchuk O.I.

**CLINICAL SYMPTOMATOLOGY AND INSTRUMENTAL
LABORATORY INDICATORS IN CHILDREN WITH TOXOCARA
CANIS INVASION**

*Higher State Educational Establishment of Ukraine
"Bukovinian State Medical University"
Chernivtsi*

Toxocarosis is a parasitic disease caused by the migration of larvae of ascaridates of dogs (*Toxocara canis*) in organs and tissues, characterized by prolonged relapsing and polyorganic lesions of allergic nature.

In the research clinical and laboratory, biochemical, instrumental, epidemiological, epizootiological, sanitary-helminthological, immunological, serological methods are used with the respective statistical treatment of the results.

Before therapy, at the examination, the patients present numerous complaints. Most of them complained of increased fatigue (59.90%), headache (30.08%), dizziness (45.25%), feeling of heaviness and / or pain in the epigastric region (40.92%) and right hypochondrium (67.48%), dyspeptic manifestations in the form of nausea (30.62%), loss of appetite (44.72%), constipation (24.66%), diarrhea (21.14%), flatulence (41.19 %). Signs of dyspeptic syndrome of varying degrees of severity are noted in half of the patients. In 46.61% of patients with toxocarosis, there are complaints of cough, more commonly dry, 14.63% of patients present complains of dispnea. Chest pain is observed in 15.22% of patients. Joint pain, mostly of moderate

intensity, is found in 15.18% of patients. In most cases, the pain is localized in the small joints of the limbs. At examination, 84.25% of patients show pallor of the skin, 14.36% have subicteriousness of sclera, and 44.72% of patients have a variety of recurrent skin rashes. The elements of the rash are maculopapular and localized on the trunk or on the trunk and upper limbs. The increase in body temperature is more often observed in 55.28% of patients, the temperature increases usually in the evening, at noon, more often it is subfebrile or febrile. accompanied by a slight chill. In an objective examination, 196 (53.12%) of children have local pain in the right hypochondrium and / or in the projection area of the gallbladder with irradiation in the right shoulder, neck, under the shoulder and in the lumbar area. In 45,53% of patients, limited pain during percussion and palpation is defined predominantly in the epigastric area, less (22.49%) around the navel. A coated tongue is encountered in 33.88% of patients. When palpation in the right hypochondrium, the liver is determined at the edge of the artery arch in 29.27% of patients, and lower edge of the liver protruded from the edge of the edge arch to 2-3 cm in 70.73%, the. The palpated liver occurs sealed, smooth, often tense. An increase in the spleen size is observed in 11.11% of children. With auscultation of the lungs, hard breathing is determined in 181 (49.05%) patients, weakened breathing in 45 (12.19%) patients and dry rales are found in 54 (14.63%),

An ultrasound examination of the abdominal organs in 61.3% of patients with complaints of pain in the right hypochondrium shows signs of chronic cholecystitis, 42.9% of patients have hepatocholecystitis, cholecystopancreatitis, hepatitis. Splenomegaly is detected in 20 (5.42%) patients and one child shows signs of gastroduodenitis. When conducting fibrogastroduodenoscopy, 43 (11.65%) patients show signs of gastroduodenopathy.

Pulmonary syndrome is observed in 48.27% of patients. On the background of subfebrile temperature, less often febrile, patients have cough, choking, chest pain. Radiographically, in 50.94% of patients, the enhancement of the pulmonary pattern due to perivascular and peribronchial thickening and infiltrative changes are determined. Hepatobiliary syndrome is detected in 69.34% of patients with toxocarosis, and in 11.11% of patients

it is accompanied by splenomegaly. In 72.37% of patients, neurological disorders of varying severity are observed, which clinically manifest themselves in the form of a headache occurring more often by the end of the day and / or after an overstrain, increased fatigue and irritability. In 41.7% of the patients, the syndrome of vegetovascular dystonia is detected, which is expressed in disruptions of the vegetative regulation and autonomic instability, which indicates a decrease in the adaptability of patients.

During rheoencephalography, there is a tendency to increase the vascular tone, mainly in the vertebro-basilar basin, venous outflow disturbance, congestion of the brain. All symptoms of toxocarosis eventually lead to disorders in the emotional sphere, that is, to emotional disturbances of a secondary nature. Changes in the emotional sphere manifested themselves in a different form of neurasthenic syndrome (asthenic-depressive, asthenophobic, asthenohypochondria), as well as hysterical syndrome and neurotic reactions.

Among the laboratory parameters in patients with toxocarosis, eosinophilia (100%), leukocytosis (80.30-93.33%), accelerated ESR (90.37-96.70%), anemia (80.51-87.88%), hypergammaglobulinemia (93.50-100.00%), hypoalbuminemia (76.62-97.04%). Similar clinical and laboratory studies are performed in children aged 1 to 14 without toxocarosis, who underwent examination and therapy at the somatic department of the regional clinical children's hospital.

Comparative analysis of the frequency of major clinical manifestations shows that in children with toxocarosis, recurrent fever, pulmonary syndrome, and lymphadenopathy are 2.5 times more frequent than in children without toxocarosis ($P < 0.01$). Abdominal syndrome, neurological disorders, hepatomegaly, skin reactions are also more common in patients with toxocarosis than in children without toxocarosis, but 1,2-1,3 times more often.

The analysis of the results of the examination of children with and without toxocarosis shows that changes in clinical and laboratory parameters in patients with toxocarosis are diverse and nonspecific, which is consistent with the literature data.

Kryvchanska M.I.*, Bulyk R.Ye.*, Pishak O.V.*
**DISRUPTION OF THE CIRCADIAN ORIENTATION OF
RHYTHMS IN HUMAN ***

**Higher State Educational Establishment of Ukraine
“Bukovinian State Medical University”*

Department of Medical Biology and Genetics

*** Yuri Fedkovych Chernivtsi National University*

Department of Health and Safety

Chernivtsi, Ukraine

“Basic” human metabolic biorhythms, essentially, evolved in humans, and later, “molecular” appeared, associated with the phased incorporation of regulatory systems: immune, endocrine, nervous, etc. As a result of natural selection, endogenous biorhythms were genetically justified.

With the development of civilization, man became less and less subject to the laws of nature, as a result of which certain disruptions in the work of biological clock occur. One of the reasons for this is the change in its synchronization. Evolutionarily, human activity depends on the time of day, for example, with the onset of darkness, the body begins to produce melatonin, which is a natural hypnotic hormone.

Today, we increasingly see the term “internal desynchronization” in the clinic. It is associated with an incorrect distribution of work and rest time, stress, work ability and high performance.

Desynchronization can be caused by disorders of the central link, as well as changes in transcription or translation of genetic information at the cell level, like a peripheral oscillator. In this case, the coordination (phase disturbance) between the rhythms in the system itself is disturbed. Desynchronization is manifested by a disruption of the operation of the internal organs due to the imbalance of the regulator, the hypothalamic SChN, and the secretory activity of the pineal gland, which synthesizes melatonin. The causes of this condition are both endogenous factors (hidden pathology) and the discrepancy between the rhythms of the body and external factors, periodic shifts that have occurred in the environment.

Here, the accomodational, adaptive nature of body reactions in response to temporary, exogenous nature, natural deviations, and

pathological desynchronization, which has a destructive nature of action, should be clearly separated.

Under normal conditions, the circadian fluctuations of a number of important physiological parameters (hormone secretion, electrolyte excretion, motor activity, body temperature, sleep-wake cycle, etc.) are synchronized with each other.

A change in the circadian structure of the rhythms is accompanied by a phase divergence, which creates the prerequisites for desynchronization. In order to prevent the formation of sustainable pathological desynchronization in treatment tactics, one should adhere to the chronoperiodic approach, which should be aimed at desynchronization and delaying periods of biorhythms.

Stepanchuk V.V.

**EFFECTS OF CADMIUM CHLORIDE ON THE CIRCADIAN
CHRONORHYTHMS OF FREE RADICAL HOMEOSTASIS IN
THE LIVER TISSUE OF WHITE RATS**

Higher State Educational Establishment of Ukraine

«Bukovinian State Medical University»

Department of Pharmaceutical Botany and Pharmacognosy

Chernivtsi

Cadmium salts are among the most dangerous environmental pollutants. Entering the body, they activate free radical mechanisms, this process is accompanied by an increase in the body's level of active oxygen forms.

The purpose of the study is to investigate the structure of circadian chronorhythms of free radical homeostasis indices in the liver tissues of white rats in the physiological norm, as well as under the influence of cadmium chloride.

The experiments are conducted on 48 adult white male rats weighing 160-180 g. The test group of animals is intragastrically imposed with an aqueous solution of cadmium chloride at a dose of 20 mg / kg for 14 days, and the control group with tapwater.

The rats are decapitated in accordance with the requirements of the European Convention for the Protection of Experimental Animals, under brief ether anesthesia at 8 a.m., 12, 4, 8 p.m., 12 and 4 a.m.

The state of the redox potential of liver tissues is studied in the homogenates of this organ by determining the indices of lipid peroxidation (LP) and the antioxidant support system (ASS). The state of lipid peroxidation is assessed by the content of malonic aldehyde (MA) and diene conjugates (DC) in the liver, and the ASS by the level of catalase.

The results obtained indicate that under normal conditions, the indices of free radical homeostasis in the liver tissues of white rats periodically change during the day. Thus, the level of MA first decrease and then grows, reaching a maximum value at 12 a.m. Acrophase of the level of DC is observed at 2 p.m., batiphase at 8 p.m. Catalase activity in the liver of control animals initially increases slightly, but subsequently acquires lower values.

In rats imposed with a solution of cadmium chloride, significant disorders of the chronorhythms of all the studied parameters of pro- and antioxidant homeostasis are recorded. In particular, the levels of MA and DC significantly increase in all the studied time intervals, and their chronograms, compared with the control, become antiphasic. The MA rhythm mesor increases from 42.56 ± 4.374 to 54.48 ± 4.436 $\mu\text{mol} / \text{g}$ of tissue, the average level of DC increases from 17.34 ± 2.321 to 28.33 ± 3.425 $\text{E}_{232} / \text{g}$ of tissue.

All these changes occur against the background of a decrease in the activity of catalase, antioxidant defense enzyme. During the entire study period, the activity of catalase compared with the groups of intact rats is significantly less. The rhythm mesor decreases from 31.67 ± 3.685 to 17.82 ± 2.483 $\text{nmol} / \text{min} \cdot \text{mg}$ tissue.

Consequently, the analysis of the chronorhythms of the indices of the pro- and antioxidant systems of the liver tissues of white rats under conditions of cadmium intoxication reveals the activation of LP on the background of antioxidant defense deficiency, which is accompanied by signs of desynchronosis. This gives reason to argue about the imbalance of the systems of free radical homeostasis, which leads to a decrease in the adaptive and compensatory capabilities of the organism.

Batig V.M., Glushchenko T.A.
**HYGIENIC STATE OF THE CAVITY IMMEDIATELY AFTER
COMPLEX TREATMENT OF PATIENTS WITH
GENERALIZED PERIODONTITIS OF CHRONIC COURSE
WITH PREDOMINANCE OF SYMPATHETIC NERVOUS
SYSTEM**

*Higher State educational institution of Ukraine Bukovinian State
Medical University, Department of Anatomy, topographic Anatomy and
operative surgery*

One of the common factors in the development of periodontal disease is the presence of concomitant somatic diseases and conditions. In the pathogenesis of inflammatory periodontal disease, the state of the nervous system, in particular, vegetative, is important. The relationship between the diseases of the oral cavity, their course and treatment on the direct depends on the state of the autonomic nervous system.

Determine the state of the oral cavity immediately after the proposed medical treatment in symptomatic patients with generalized chronic periodontitis.

In the treatment of patients with chronic periodontitis chronic course, the state of the autonomic nervous system was taken into account. Evaluation of the state of the autonomic nervous system was carried out by determining the Kerdo index. In our study, the main (first) group was 40 (66.67%) patients with generalized periodontitis with a predominance of the sympathetic nervous system, which was used in the complex treatment of the proposed scheme of medical therapy: prescribed a course two days before each dental visit "Anaprilin" 0.01 g - 1 tablet 2 times a day, tincture of valerian 25 drops 3 times a day and "Doxazosin" 0,001 g - 1 tablet 1 time per day, as well as the fact that after a dental intervention prescribed a course of 3-5 days: "Ibuprofen" 0.2 g- at 2 tablets 3 times daily, valerian tincture 20 drops 3 times a day, " Anaprilin " 0.01 g - 1 tablet 4 times a day and "doxazosin" 0,001 g - 1 tablet 1 time per day.

The group of comparison (the second) was 20 (33.33%) of patients with generalized periodontitis, which in the complex treatment was performed similar to the patients of the main subgroup of treatment, but without medication premedication.

The course of treatment for patients with generalized periodontitis and the degree of the main group on average was 5.35 visits, the comparison group - 8.22 visits. In order to achieve stabilization of the dystrophic-inflammatory process in patients with generalized periodontitis II degree it was necessary: 7.33 visits to patients in the main group and 9.12 visits to patients in the comparison group.

After a comprehensive treatment, patients from both groups noted improvement in general well-being, the disappearance of unpleasant sensations and mouth odor, gum pain and bleeding. Objectively, the mucous membrane of the gum acquired a pale pink color, densified, firmly covered the hard tissues of the tooth.

Conducted complex treatment has led to a significant improvement in the hygienic status of patients with generalized periodontitis. This is evidenced by the positive dynamics of the ONI-S index of hygiene. In the patients with the 1st stage of generalized periodontitis of the main group, the ONI-S index of hygiene decreased from 1.57 ± 0.09 points to 0.55 ± 0.05 balls; in patients with II degree of disease the index decreased from 1.91 ± 0.05 to 0.79 ± 0.06 ball. In general, in the patients of the main group, the index of ONI-S decreased by 61.49% from 1.74 ± 0.09 points to 0.67 ± 0.06 points, which corresponds to the level of good oral hygiene.

In patients with I degree of generalized periodontitis, the comparison group of the ONI-S index of hygiene decreased from 1.59 ± 0.08 points to 0.75 ± 0.06 , while in patients with II degree of disease the index decreased from 1.98 ± 0.06 to $0,86 \pm 0,04$ points. In general, the patients in the comparison group decreased the value of the index of hygiene by 54.75% from 1.79 ± 0.08 points to 0.81 ± 0.06 points, which also corresponds to the level of good oral hygiene.

After treatment of patients with generalized periodontitis with a predominance of sympathetic autonomic nervous system with the use of the proposed medication premedication, they marked a significant improvement in the periodontal state: in 96.15% of patients. The proposed treatment technique allows to eliminate the manifestations of inflammation and achieve stabilization of the dystrophic-inflammatory process in the periodontium in shorter periods of treatment. In the nearest terms of observation, earlier and expressed normalization of clinical and

laboratory parameters that characterize the dystrophic-inflammatory process in periodontal disease is noted. The obtained data testify to the expressed favorable effect of the proposed premedication in the treatment of patients with generalized periodontitis with the predominance of the sympathetic vegetative nervous system.

The analysis of the results of the clinical and laboratory research carried out immediately after the complex treatment showed the high therapeutic effectiveness of various forms and ways of influencing the periodontal of the proposed medicinal products.

The prospect of further research is the development of methods for treating patients with various forms of periodontitis, taking into account the state of the autonomic nervous system.

Kuchuk O., Ganchuk G., Zemliak O., Kuchuk N.

**CLINICAL FEATURES OF THE EYE INJURIES IN THE
PATIENT OF THE REGIONAL OPHTHALMOLOGICAL
TRAUMATOLOGY CENTRE**

Higher State educational institution of Ukraine Bukovinian State Medical University, B.L. Radzihovskyi Department of ophthalmology

Nowadays eye injury is still one of the main cause of blindness and occupational disability. The purpose of our work was analyze the structure, features of the clinical progression of the trauma of the organ of sight in patients treated in ophthalmological traumatology centre (Chernivtsi city) for 2018. Data of 2508 patients with eye injuries were processed and 120 medical history of injured patients, who needed hospitalization, were analyzed. The criteria of differentiation were age, gender, mechanism of injury, circumstances in which the injury was received, state of the eye during hospitalization, type of emergency care, type of the therapy, state of the eye following discharge from hospital.

Among all injuries of the eyeball and appendages of the eye (120 cases), penetrating wounds were amounted 31,7%, non-penetrating –

6,7%, burns – 4,2%, contusion – 40,8%, eyelids damage – 10%, conjunctival damage – 5,8 %, damage of the tear organs – 0,8%.

The tearing of eyelids was observed in 3 patients (2,5%) of all eye injuries.

Mostly in 2018, eye injuries were received by men: 70,8% of the total number of all injured adults. Of these patients, men of working age constituted 85%. As for women, the injury was received at the age of 61-80 years old the most commonly, which was 54,5%.

Among children, only boys were injured: 7 persons (100%).

The hemorrhages in the eye were constituted 101 cases (including that one patient had several hemorrhages, for example: hematoma of the eyelids, hyphema and hemophthalmia): hematoma of eyelids – 23 (22,8%), subarachnoid hemorrhage – 19 (18,7%), hyphema – 30 (29,7%), hemophthalmia – 24 (23,8%), hemorrhage in the retina – 2 (2%), retrobulbar hemorrhage – 3 (3%).

Crystalline lens injuries were observed in 12 cases among patients with eye injuries. Among them: subluxation of the lens – 5 cases (41,7%), luxation of lens – 2 cases (16,6%), traumatic cataract – 5 cases (41,7%).

Conclusions:

The vast majority of injured patients, who resorted to regional ophtalmological traumatology centre, were men of working age. Owing to the activity of the centre on the basis of the regional clinical hospital in Chernivtsi city, all patients, who applied for medical aid, received a highly qualified ophtalmological care, which corresponded to the III-th level of medical care.

Marynychyna I.M., Pecheriaga S.V.

ASSESSMENT OF BLOOD CIRCULATION IN THE SPIRAL ARTERIES IN DYNAMICS DURING I TRIMESTER OF GESTATION

Higher State Educational Establishment of Ukraine “Bukovinian State Medical University», Department of Obstetrics, Gynecology and Perinatology, Chernivtsi

Physiological development of pregnancy is associated with adequate vascularization of the terminal villi and development of the vascular bed of the fetal part of the placenta causing decrease of the vascular resistance in the umbilical cord artery and its branches. Considering the above we have assessed the blood circulation in the spiral arteries in case of physiological pregnancy in the dynamics of I trimester of gestation.

60 primiparas with physiological course of I trimester of gestation were examined. All the pregnant women were examined according to the Order of the Ministry of Health of Ukraine № 417. Ultrasound examination was conducted in dynamics from seven to twelve weeks of pregnancy. By means of Doppler examinations we have got spectra of the blood circulation rate curves in the spiral arteries supplying blood directly to the villous chorion. In the spiral arteries all the resistance indices (SDR, RI, PI) in dynamics of I trimester of gestation decreased to some extent. The blood circulation rate curves of the spiral arteries possess relatively high rate of diastolic blood flow, which increases in dynamics of I trimester. In their turn, the indices of vascular resistance in the spiral arteries are much lower than those of the uterine ones. Assessment of the character of hemodynamic curves demonstrated that the parameters of the peripheral vascular resistance ranged in dynamics of I trimester of pregnancy respectively: SDR – 2,57-2,7, PI – 0,55-0,6, RI – 0,96-1,2. The curves of blood circulation rate, that is PSR and FDR increased a little, the indices of the average diastolic rate (ADR) and peak rate averaged by the time were reliably unchanged.

Analysis of the obtained data resulted in the fact that the highest intensity of hemodynamics in the pool of the uterine arteries during 11-12

weeks of gestation was registered in the group of patients with favourable consequences of pregnancy.

The obtained data enabled to draw a conclusion that physiological gestation is most characterized by the lack of blood circulation registration in the intervillous space in the first trimester of pregnancy.

In the dynamics of I trimester of gestation decreased resistance indices are found both in the uterine and spiral arteries, and blood circulation rate increases, and these processes are more pronounced in the spiral arteries.

Kosilova S.Ye.

**INVESTIGATION OF RISK FACTORS PROMOTING
INTRAUTERINE GROWTH RETARDATION OF FETUS**

*Higher State Educational Establishment of Ukraine “Bukovinian State
Medical University», Department of Obstetrics and Gynecology,
Chernivtsi*

Intrauterine growth retardation (IUGR) of the fetus remains one of the most topical issues of modern obstetrics, since it results in birth of babies with low body weight for the term of gestation. According to the data suggested by different authors it ranges from 5 to 31,2 %, and among preterm babies it reaches 42 %. Literary data are indicative of the fact that perinatal mortality of babies with IUGR is 3-5 times as much as an average in the population, and the neonatal period develops with complications 1,5 times as much.

With the aim to study risk factors promoting IUGR of the fetus 40 delivery case histories with this pathology were analyzed. The study resulted in the following findings: availability of TORCH-infection – in 30 (75%) of women, II degree anemia – in 12 (30 %), chronic gastrointestinal diseases – in 18 (45%), chronic kidney diseases – in 10 (25%), cardio-vascular diseases – in 10 (25%), endocrine pathology – in 8 (20 %) of patients.

Analysis of the development of pregnancy found placental insufficiency in all the examined women (100%), occurring both during

the early and late terms of gestation. Hormonal insufficiency was found in 28 (70%) women (decreased content of progesterone and placental lactogen, increased Dehydroepiandrosterone sulfate), threat of miscarriage in different terms of gestation – in 30 (75%), early and late toxicosis of pregnancy – in 8 (20%), placental presentation – in 2 (5 %), immune conflict during pregnancy – in 4 (10 %), exacerbation of chronic extragenital diseases, genetic pathology and maldevelopment of the fetus in 2 (5%). Chronic alcoholism and drug addiction were of certain importance as social-economic factors.

Irrespective of a comprehensive treatment delivered to the pregnant women in 5% antenatal death of the fetus was registered. The rest of the women gave birth to a child including delivery through the natural maternal passages in 16 (40%) patients, and by means of cesarean section – in 22 (55%). The body weight at birth was on an average 1651 ± 172 g. Delivery was preterm in all the patients: at 29 – 30 weeks – in 4 (10 %) of the examined, at 32 – 34 weeks – in 20 (50%), at 35 – 37 weeks – in 16 (40%). 2 infants died at the early neonatal period. The newborns with IUGR often developed congenital malformations (5 %), intrauterine hypoxia and asphyxia (75%), respiratory disorders and pulmonary hemorrhages, decrease of the functions of the vital organs.

Conclusion. Thus, IUGR refers to complications of the prenatal period resulting in increased sickness rate and mortality of fetuses and neonates, causes a high level of abdominal delivery. Therefore, rational planning of pregnancy, timely examination, finding all the risk factors, and their elimination if possible, in women with examined somatic and obstetrical-gynecological anamnesis will enable to reduce the indices of perinatal morbidity and mortality, and improve health of Ukrainian population.

Proniaiev D.V., Bulyk R.Ye., Proniaiev V.V.
**PECULIARITIES OF MORPHOLOGICAL
TRANSFORMATIONS IN THE VAGINA OF 4-MONTH
FETUSES**

Higher State Educational Establishment of Ukraine "Bukovinian State Medical University", Department of Medical Biology and Genetics, Department of Anatomy, Topographic Anatomy and Operative Surgery

In 4-month female fetuses the posterior surface of the bladder borders on the uterine body and cervix. The latter is forward inclined at an obtuse angle to the vagina. The vagina looks like a tube filled with pasty white mass. Supravaginal part of the uterine cervix is covered with the peritoneum and separated from the lower part of the posterior wall of the bladder by a thin layer of spongy cellular tissue. In male fetuses the peritoneum from the upper posterior surface of the bladder passes from the back to the anterior surface of the rectum and forms rectovesical depression, and in female fetuses – on the anterior surface of the uterus forming vesicouterine depression. The latter looks like a slit 6,5-8,5 mm deep on the sagittal section. Longitudinal folds of the mucous membrane of the uterine cavity are lacking. The uterine fundus in 4-month fetuses is not developed and located lower the level of the uterine tubes emerging. In the majority of fetuses the upper inconsiderable part of the vagina is adjacent to the lower part of the posterior wall of the bladder and separated from it by a thin layer of the spongy cellular tissue. In the pelvic region the vagina forms an inflection curved backward, and while passing into the perineal portion – curved backward. The rectum forms two lateral inflections in the frontal plane directed by their convexity to the right and left. The rectum is filled with meconium to some extent. The contraction muscle of the vagina 2,2-4,6 mm long is presented with single fibers which embrace the vaginal vestibule and cover vestibule bulbs in the form of a tape. The levator muscle of the anus is usually tetragonal in shape. Internal (middle) bundles of the pubococcygeal muscle, as a part of the levator muscle of the anus, are closely adjacent to the lateral walls of the urethra and vagina, and are attached to the anterior and lateral walls of the rectum. In 6 out of 10 examinations of 4-month female fetuses the middle bundels of the pubococcygeal muscle grow together with the posterior part of the lateral vaginal walls.

Proniaiev D.V., Bulyk R.Ye., Sovrea Alina
**TOPOGRAPHIC-ANATOMICAL UTERINE
CHARACTERISTICS OF THE FETUSES IN SECOND
TRIMESTER**

Higher State Educational Establishment of Ukraine "Bukovinian State Medical University", Department of Medical Biology and Genetics, Department of Anatomy, Topographic Anatomy and Operative Surgery

The examination of fetuses of 4-6 months of development found certain peculiarities of the structure, syntopy and topography of the uterus. 5 out of 30 fetuses had insignificant deviation of the uterine vertical axis in the frontal plane to the right. The degree of this deviation is likely to depend on the interrelation of lengths of the uterine round ligaments. Thus, in 5 cases the right uterine round ligament in fetuses of 4-6 months was shorter than the left one. An average length of the right uterine round ligament was 6,5 mm, of the left one – 7,1 mm. As to the deviation in the sagittal plane, the positions anteflexio or retroflexio were difficult to identify. In all the cases the uterus was in the intermediate position. Syntopically, in all the cases the uterus touched the anterior wall of the rectum with its posterior surface, and the posterior surface of the urinary bladder – with its anterior surface. Umbilical arteries passed from the sides at 1 mm distance. The ovaries were characterized by the biggest variety of syntopic interrelations with the uterus. In the majority of early fetuses – 8 out of 10 fetuses of the 4th month of development – the ovaries were in high position and touched the posterior surface of the uterus with their lower extremities. The high position was characterized by the ovarian localization either longitudinally the lateral walls of the rectum or in the femoral regions. In 2 cases in 4-month fetuses the ovaries were located behind the uterus by their bigger part. This position was characteristic for the majority of fetuses of the 6th month of development. The uterus shape, or to be more exact, the shape of the uterine floor was characterized by the biggest variety of morphological signs. In 26 fetuses out of 30 the uterus

was flat from 1 to 2,5 mm thick. In 4 fetuses the uterus was of the shape close to the triangle. The uterine floor of 4-month fetuses was characterized by the following shapes: flat – 2 cases, convex – 1 case, channel – 5, tuberoso – 2. In half of the cases of 4-month fetuses (5 out of 10) the uterine floor was of a channel shape. This shape was characterized by the presence of sulcus along the centre of the uterine floor as of separating it into two parts. In our opinion, such a structure can be qualified as a normal one for the given period of development, and it is the sign of continuation of embryonic morphogenesis. In 2 cases the uterine floor was tuberoso characterized by the presence of tubers in the mouth area of the uterine tubes. We consider this variant is the result of flattening of the sulcus which presence is characteristic for the majority of fetuses of the given age period and descending of the uterine tubes. In two cases the uterine floor was flat which is indicative of disappearing of its sulcus. In one case the uterine floor was convex which is indicative of accelerated development. In 5-month fetuses a regular distribution of uterine shapes was found. In 3 cases the shape was tuberoso, in 3 more cases – channel, in 2 cases – flat, and in 2 more cases – convex. In 6-month fetuses flat shape of the uterine floor prevailed (7 out of 10). There was one case of a channel shape, one tuberoso, and one convex. The peculiarities of the uterine morphology found are indicative of characteristic belonging of a certain shape to the period of development. The regulations of morphogenesis of the uterine floor shape from channel to flat can be accordingly observed. Finding a channel uterine shape in 6-month fetuses may be indicative of a retarded development and possibility to form congenital defects.

Zavolichna T., Zrybnieva.K.

THE PROJECT MANAGEMENT ASPECTS OF CROSS-BORDER COOPERATION

Yuriy Fedkovych Chernivtsi National University, Ukraine

Cross-border cooperation is one of the promising ways of balancing disparities between adjacent territories in the economic, social, scientific, technical, cultural, educational, environmental and other areas, as well as the unifying factor of Ukraine's European integration aspirations. At the present stage, the most effective way to solve common problems of development and deepen mutually beneficial contacts between the populations of adjacent border areas is the formation and implementation of multilateral projects and programs. Thus, Ukraine received the largest share of financial resources for the implementation of cross-border projects in the framework of cross-border cooperation programs of the European Neighbourhood and Partnership Instrument (PTS ENPI). The results of Ukraine's participation in the ENPI programs are shown in Table 1.

Table 1

Summary information on the results of the ENPI Programs

Joint Operational Program	Total budget, million euro	Share of Ukraine, million euro	Number of projects implemented, units
"Poland-Belarus-Ukraine 2007-2013"	186,201	47,250	117
"Romania-Ukraine-Republic of Moldova 2007-2013"	126,718	37,651	140
"Hungary-Slovakia-Romania-Ukraine 2007-2013"	68,638	25,578	136
"Black Sea Basin"	25,697	3,212	57

Management of cross-border cooperation projects in the process of their implementation involves substantiating the idea, essence, assessing the effectiveness of making managerial decisions, coordinating efforts to

achieve the goals, controlling the value, and quality of work. However, recently there is a problem of efficient administration of developed cross-border projects, that is, there are risks of violating all established economic, social and cultural contacts yet.

In particular, the Chernivtsi region within the framework of the Joint Operational Program "Romania - Ukraine - Republic of Moldova" implemented 28 cross-border projects with a total value of more than 13 million euros in various spheres of life of our territorial communities. However, only six of these 28 projects were recognized as being successful. This testifies to the unprofessional nature of project managers and the inefficient use of funds.

It is the ability to substantiate the ideas and the essence, the assessment of the effectiveness of management decisions, the coordination of efforts to achieve the objectives of the projects, the constant control of costs, can lead to cross-border cooperation to a more qualitative level.

An example of successful project management was the process of administering of project MIS ETC Code 1995 «Strengthening of communication relations between the blind in cross-border region». Project was funded by the European Union project and was facilitated access to information in a blind people cross-border region. The project was implemented within the Joint Operational Program Romania - Ukraine - Republic of Moldova 2007-2013. Budget of the project is 164 980.00 EURO (EU Contribution: 148 482.00 EURO – 90%). Purpose of the project - reducing isolation of blind people in the target area (Chernivtsi region, Suceava county and Chisinau) by creation of technical base and favourable conditions for communication, trainings, job search and culture exchanges for the blind through borders.

The importance of this project cannot be overemphasized. Access to the global information network for the visually impaired is much more important than for sighted people. Using the capabilities of specific Internet equipment, blind people can socialize, find like-minded people and friends, make a successful life or business decisions, be employed and implemented without barriers and borders. During the 12 months of cross-

border project realization most valuable property was a cooperation between the partners, which is an example of successful European communication. The project was implemented by Chernivtsi Regional Organization of Ukrainian Association of Blind People (have 1000 members) in collaboration with the Romanian Association of the Blind-Suceava Branch Office (has about 2000 members-blind people), Moldova Blind Union (has about 9500 members all around Moldova and about 1100 in Chisinau region) and Bukovinian Centre for Development. As project collaborates from three countries have much in common: the same needs to reduce the isolation of people with visual impairments. In frame of project was creation and opening two modern computer classes in Chernivtsi and Chisinau (10 workplaces in each country) and update computer class in Suceava. That made it possible to increase the level of education and competitiveness blind people by special technical equipment: voice typing on the screen and voice read text from the screen, speech synthesizer that provides a translation of any language of the world; each keyboard keys can "talk". Also was been provided spatial comfort and was used energy-efficient technologies in the repair and equipping computer classes. Moreover, for the Blind-Suceava Branch Office was purchased bus to facilitate transport links and for expanding communication opportunities between blind people in Ukraine and Moldova. As part of the project activities in Chernivtsi was organized jubilee 10th International Festival "Bukovina patterns", which will be attended by Blind organizations from Europe.

Another achievement of the project, in addition to equipping blind organization is to develop managerial and organizational capabilities of partners that we got in the implementation of joint project activities in three countries and in true partnership with officers BRCT from Chernivtsi and Suceava. Together we as Europeans have learned to find optimal design solutions; comply with the requirements of the EU and audit their own countries; consolidate the foundations of European democratic values in their four organizations, local authorities and residents in 3 cross-border regions of the project.

Project Results:

1) The access to print, audio and Internet information has become more wider due to the purchased equipment and life communication has become more simple and “nearer” due to the purchased bus;

2) Blind people in cross border region has become more trained and able to use their new skills and capabilities in different fields of the life;

3) Communication network between blind people in Chernivtsi region, Suceava county and Chisinau city has become more wider and people-to-people connections be strengthened;

4) Cultural exchange between the blind people be promoted by conducting of international festival «The Bukovina Patterns»;

5) Awareness of local inhabitants, local authorities, Maecenas and other interested parties about blind people problems in target region was increased;

6) Management and organizational capacities of the applicant and project partners was increased.

This project has become an effective and resonance tool for expansion of communication between the blind, attracting resources of all countries to reduce the isolation of the blind, the ability to make the world brighter and kinder in which all people, including the blind have equal opportunities for self-realization.

In order to further effective implementation of cross-border cooperation projects, it is necessary:

Firstly, that all available methods and means of managing investment projects satisfy real domestic conditions and requirements for implementation of joint projects of cross-border cooperation;

Secondly, to prepare specialists in management of investment projects that are able to provide this process in practice, in particular when implementing joint projects of cross-border cooperation;

Third, to form a market for investment projects management as a conscious need for using this tool in managing change.

Zrybnieva.I., Zavolichna K.

**PROSPECTS OF DEVELOPMENT OF PUBLIC-PRIVATE
PARTNERSHIP IN THE MEDICAL SPHERE IN THE CONTEXT
OF SOCIALLY RESPONSIBLE MARKETING**

Yuriy Fedkovych Chernivtsi National University, Ukraine

Today in Ukraine there is a powerful request for qualitative changes in the context of public-private partnership in the medical field based on socially responsible marketing. Thus, according to the Ministry of Health of Ukraine at the beginning of 2019, more than half of Ukrainian chose their doctor and 76% of them are satisfied with the quality of services. Even more patients have access to quality medicines and absolutely all - to effective vaccines for the National Vaccination Schedule. Medical institutions that have already entered into contracts with the National Health Service of Ukraine (NSSU) have begun to receive payments on the principle «money follows the patient». Effective communal primary health care institutions received payments from the NSZU up to two times more than it was with the old financing model - only in January did the NSZU pay for medical institutions under contracts of 1.5 billion hryvnias for primary care services provided to patients. Thus, a new paradigm of relations between the state, medical institutions and customers, combining market and ethical interests, was born in Ukraine. This new relationship concept is developed on the principles of social marketing.

Social marketing differs from commercial marketing mainly in its goals. If the goal of a commercial organization is to make a profit, and this goal is achieved by a marketing strategy, then social marketing is a new concept of social responsibility of all members of society. Social marketing aims to change the behaviour of large groups of people in order to achieve social harmony in society. It allows you to show the

attractiveness of your offers on the market and "sell" the product, even if it is an abstract idea, model of behaviour or a party.

In the medical field, the context of socially responsible marketing manifests itself as an adjustment of the economic category "efficiency equals profitability" to the category of ethics - that the preservation of health as a component of human potential is the main modern trend.

The basis of such a system are:

- provision of health care institutions with sufficient financial resources;
- a clear distinction between the sources of funding for each type of medical activity;
- responsibility of state and local authorities, especially OTG, for the timely and full funding of health care institutions;
- ensuring public control over the use of budget funds in the health care system at the national and local levels;
- ensuring the financial interest of private business entities in the development of the health care system.

Therefore, today, the importance of forming a partnership system as a constructive mechanism of interaction between public authorities, private capital and the public sector to solve problematic issues in the health sector is growing. Social marketing strategically connects the interests of the state - the development of social capital; private firms - providing real and potential labour; medical institutions - providing quality services to ensure their own economic efficiency and the individual as the main beneficiary, who will receive high-quality medical services and the optimal ratio of their price and quality. Such a partnership model of health care development should include the unity of medical science, the development of a system of continuing medical education, international partnership with leading countries and scientific centres, the

protection of intellectual property, the creation of targeted interdepartmental medical scientific programs and public-private partnership. Today, businesspersons can be co-organizers of the health services provision, subject to preservation and improvement of the quality of medical services at the expense of public funds. At the same time, the state order should provide: guaranteed by the state level of free medical care; national medical programs designed for extraordinary cases, the implementation of which provides for the financing of a separate item from the state budget; targeted government programs aimed at solving the problems of medical science and education.

Note that despite a certain success of medical reform in Ukraine there are a large number of doctors of pre-retirement and retirement age (50% of physicians, 30% of paediatricians and 20% of family doctors), who are partially not ready for new challenges, some of them are not ready to work with a computer "there are very active doctors at this age, they work. Therefore, more attention must be paid to the quality of personnel policies, the observance of social guarantees and human values. In the future, there is the possibility that local self-governments, especially OTGs, finance young people going to higher educational institutions and test the idea of mobility programs for doctors.

However, for the effective integration of the interests of the state, business and patients, appropriate conditions have to be created: a legal and regulatory framework adapted to the norms of the European Union, which envisages the formation of mutually beneficial relations; effective management of financial resources of the health care institution; skilled staffing and creating an attractive environment for employees; availability of modern high-tech equipment for diagnostics, treatment and prevention of diseases; meeting the needs of patients by improving the quality and expanding the range of medical services.

Thus, the effective implementation of public-private partnership on the principles of social marketing in the health care system of Ukraine, on the one hand, will allow avoiding shortcomings of direct regulation of the state, and on the other hand - «marketing failures».

Babukh I., Bordeniuk Y.

**FORMATION OF NEW MANAGERS COMPETENCIES OF
MEDICAL INSTITUTIONS IN THE CONTEXT OF
REFORMING THE MEDICAL INDUSTRY**

Yuriy Fedkovych Chernivtsi National University, Ukraine

In Ukraine, medical reform continues, which in fact can be called national, because its goal is to ensure all Ukrainian equal access to quality medical services. In strategic management, this means a transition to a new concept of the health care system, in the centre of which is the patient. Over the last two years, the transition to new forms of financing of medical institutions, forms of remuneration, requirements for competencies of family doctors and, accordingly, to heads of medical institutions has been implemented. In general, we can summarize - with the rapid pace of decentralization in Ukraine in medical institutions, the need for such specialists will increase, and among the strategic directions of reforming domestic health care, the formation of a new generation of managers - modern managers should occupy the main place. That is why the development of the personnel potential of medical personnel is a priority of the new European policy "Health - 2020".

Thus, at the end of 2017, the National Health Service of Ukraine (hereinafter referred to as NSAH), the central executive body, was established to pay for medical services rendered to the patient in the interests of the patient (state budget funds under the medical guarantee program). That is, the patient receives the service and the state pays for the medical institution for it. The cost of services will be determined on the basis of uniform national basic tariffs and quality requirements, which in reality must be calculated by local managers. In this aspect, the head of the medical institution should be more a manager, not the laws of economic theory, and not a good doctor. Attention should be paid to the fact that managers of medical institutions in developed countries of the

world are specialists in economic or legal education, the so-called medical managers, and in Ukraine most of the managers in the field of health care are specialists with no experience and skills of public administration who have medical education and most of which do not have legal or economic training.

Note that in modern management science there is a distinction between the essence of the concepts “specialist in public health management”, “manager in healthcare” and “head of a medical institution”. For example, the scientist Pozhivilova A., differentiates and adapts these concepts to the realities of domestic medicine as follows:

- the specialist in public health administration is a public servant, as a rule, a doctor by profession, who holds a particular position in the public service in the field of health care (for example, the head of the district office works in the regional health administration);

- the manager in health care is, first of all, not a public servant, often not a doctor, who works in a medical institution or heads it and performs organizational work on the realization of an order on a contract basis. As a rule, the manager may have a legal or economic education;

- the head of a medical institution is a technological profile manager who provides overall management of various medical technological processes, coordinates the activities of its individual units and combines the efforts of the team to achieve the goal and obtain high results.

They all perform the same function - management, that is, there is an increase in the role of managers, economists and administrative workers in the field of health care. Note that clinics abroad are usually managed by professional managers who do not have medical education. In European countries, public health management personnel are medical managers, that is, specialists who are supporters of control in public administration of the health system and in the management of medical institutions.

Medical managers are divided into two types: managers of general qualification and managers-specialists. The managers of general qualification are responsible for the overall management of the medical institution and organization. And professional managers are responsible for the effective management of specific areas, such as analysis of management decisions and strategies in the health care system, finance, accounting, budgeting, marketing or human resource management.

For example, in EU countries, training of public health managers is usually due to a program in a business school (business administration with a specialization in health management), and in some health institutions, an administration or health management I through public health schools.

Now the Chief Doctor performs all administrative and medical functions in Ukrainian health care facilities. This is a huge array of works, which in many developed countries of the world is carried out by two specialists - the general director deals with the main administrative issues, and the medical director - in all medical processes. Therefore, for Ukraine, the issue of building an effective system of training managers in the field of health care remains extremely important.

One of the main areas of HR policy in the field of health care should be a continuous review of the directions of education and postgraduate training of leading personnel of the industry; correct selection and placement of personnel, their promotion both horizontally and vertically; creation of information base of managers for efficient use of trained personnel. After all, it is the proper maintenance of the conditions for the performance of the duties of the leaders, their theoretical training and practical experience of work is inseparable from the consequences of the implementation of management decisions taken in the state.

Zeyad Muhammad, Olga Kushniryk

A TREATMENT FOR PERIPHERAL NERVE PARALYSIS

Higher State Educational Establishment of Ukraine “Bukovinian State Medical University”, Chernivtsi, Ukraine

Peripheral nerve palsies are a peripheral nerve disorder that may result from trauma, injury, genetic disorder or another nerve problem, nerve compression or another disease, such as diabetes, but in that case the upper limb nerves will be not fully damaged cause even if there is a 10% of the nerve alive, here is a chance to treat it again. According to the mentioned above, an aim of our manuscript was to describe the result of experiment with injured zone of nerve.

Prosthetic implant is an artificial device that replaces a missing body part, which may be lost through trauma. Prostheses are intended to restore the normal functions of the missing body part. Amputee rehabilitation is primarily coordinated by a physiatrist as part of a inter-disciplinary team consisting of physiatrists, prosthetists, nurses, physical therapists and occupational therapists. Prostheses can be created by hand or with CAD (Computer-Aided Design), a software interface that helps creators visualize the creation in a 3D form, so in February 2014 some scientists managed to design an artificial hand with real feeling. It's a new nerve interface gives a sense of touch to a prosthetic. The control of injured nerve occurs definitely in medical engineering way, that is why creating of external axon to send signals to the muscles naturally will be an alternative way, skipping the injured zone of nerve. Methods of doing it is imagining to use an electrode connected with the undamaged part of the neuron to measure the signals and after that connecting that electrode with a specially created sensor combined directly with the other undamaged part of the nerve. This link will participate in sending the right signals to all the muscles of hand like it's coming from the CNS and after that it's supposed the injured hand to be easily moved naturally after some physical therapy exercises.

Thus, an injured hand by paralysis can be controled with peripheral nerves by an external axon transferring signals from one part to another undamaged part to be connected by the muscles got alive again.

Ujjwal Awasthi, Olga Kushniryk

GLOBAL DISTRIBUTION OF SCHISTOSOMIASIS DISEASE

Higher State Educational Establishment of Ukraine “Bukovinian State Medical University”, Chernivtsi, Ukraine

Schistosoma most commonly known as blood fluke is the cause of second most socioeconomic devastating parasitic disease after malaria known as schistosomiasis. The target groups effected by the disease are the school children in the endemic regions or people (adults) with occupation involving contact with contaminated water (fisherman, farmer and irrigation workers). In this regard, estimation of global distribution of schistosomiasis disease was an aim of our manuscript.

The latest global reports show that schistosomiasis is mostly prevalent in tropical and subtropical regions especially in poor communities lacking safe water and adequate sanitation. According to survey in 2016 at least 206.4 million people required preventive treatment. Estimates show that people requiring treatment, at least 91.4% are living in Africa. The geographical distribution of schistosomiasis is acquired by travelers reflect travel and immigration patterns. Frequently visited sites in Africa are the common ground of infections, areas are sites of rivers and lakes like the rivers Nile, Omo and Zambezi. Sub Sharan region is the most susceptible for acquiring schistosomiasis. Most of the water sources in Africa are contaminated and a local claim of safe water source cannot be trusted. In 2000 the World Health Organization (WHO) estimated a death rate of 200 000 people globally. This should have decreased considerably due to large scale preventive chemotherapy over past decade. In the last decade there has been focus of preventive campaign in the sub Saharan region where most susceptible population lives.

Thus, because of the lack of safe water, poor sanitation, lack of health education and snail control schistosomiasis is widely spread in countries of tropical region, where preventive measures should be done in wide range.

Abhishek Kumar, Olga Kushniryk

**RECENT APPROACHES IN THE DIAGNOSIS AND
TREATMENT OF NAEGLERIA FOWLERI INFECTION**

Higher State Educational Establishment of Ukraine

“Bukovinian State Medical University”, Chernivtsi, Ukraine

Naegleria fowleri – is a rare infection that penetrates through the nose in fresh water. This organism can travel up from nose to brain causing infection called primary amoebic meningoencephalitis known as PAM which destroys brain tissue and causes brain swelling and death. Due to the medical importance of this disease, the goal of our review was to make cases report on PAM and describe the most effective methods of its diagnosis and treatment.

People can get infected while swimming or diving in warm fresh water in lakes or rivers. Initial symptoms begin 1 to 7 days after infection from headache, fever, nausea, vomiting and stiff neck to later it may cause confusion, loss of balance, hallucinations, seizures and coma. After the start of symptoms, the disease progresses rapidly and death usually occurs within 5 days (range 1-12 days). PAM cannot be spread from person to person. According to Centers for Disease Control and Prevention (CDC) report 138 people are known to be infected in USA since 1962 and just 3 survived in 15 southern states. Fatality rate is nearly about 97%. An infection can be diagnosed in laboratory by detecting *N. fowleri* organism in cerebrospinal fluid, biopsy, tissue specimens. It can be stained with Giemsa-Wright or with modified trichrome stain for identification. Treatment of PAM, including amphotericin B, miconazole, fluconazole, ketoconazole, rifampin. Complex drug miltefosine and hypothermia have been employed in treatment. NGS (Next Generation Sequence) including few approaches is a great evolution for the early diagnosing and treatment of *N. fowleri* infection. These recent technologies allow us to sequence DNA and RNA much more quickly and cheaply than the previously used.

Thus, to decrease in the human mortality rate from *N. fowleri* infection complex methods of treatment should be applied.

Kartik Sharma, Olga Kushniryk

TRANSMISSION PECULARITIES OF PTHIRUS PUBIS

Higher State Educational Establishment of Ukraine

“Bukovinian State Medical University”, Chernivtsi, Ukraine

Pubic, or crab louse (*Pthirus pubis*) is an obligate ectoparasite that feed exclusively on the blood. It is found exclusively in the pubic hair or sometimes in the axillae as these regions are rich in the apocrine gland. Pubic lice can be found in all parts of the world, affecting men and women of all races. Animals do not carry or spread pubic lice. However, pubic lice can move and spread from one person to another on clothing, bedsheets, towels, or other shared items, causing itching and significant discomfort. Due to the medical importance of this species, the goal of our abstract was to estimate the peculiarities of its transmission.

According to Armstrong N. (2006) West Yorkshire, UK, an idea of Brazilian hypothesis was suggested which states grooming of Pubic hair being linked to the lower cases of crab louse. A new research between 2003 and 2013 at Milton Keynes General Hospital shows that men were overwhelmingly crabbier, with an incidence of 82% male, 18% female infections. A case presented at Department of Skin and VD, Patna Medical College and Hospital, India confirms the sexual transmission of the pubic louse. Examination revealed excoriation marks in the pubic region and no suggestion of tinea, scabies, or contact allergic dermatitis. Polarized videodermoscopy revealed “crab”-like pubic louse with a broad body and six legs bearing thick claws grasping pubic hair. Dermoscopy of a plucked pubic hair displayed a brown-colored viable nit with an operculum at one end. Dermoscopy of a plucked pubic hair demonstrated a nit with a viable nymph. The claws of these lice are remarkably adapted to grab onto pubes and are therefore very difficult to dislodge. They rarely are found on the human head as the hair are densely packed and is too fine to be a comfortable home for lice.

So, at this time an accurate information about total number of people in the world having pubic louse is absent as neither WHO nor the US CDC collect the incidence data. The average infestation rate seems to be about 2% whether it’s measured in college students. Pubic lice have traveled with humans for over 3 million years and it is unlikely that they are at risk of extinction, other than in Western, wealthy populations.

Sohila Elkady, Olga Kushniryk
**CLEIDOCRANIAL DYSOSTOSIS CAUSED BY RUNX2 GENE
MUTATION**

*Higher State Educational Establishment of Ukraine
“Bukovinian State Medical University”, Chernivtsi, Ukraine*

Cleidocranial dysostosis is a skeletal dysplasia inherited in an autosomal dominant manner and is characterized by intramembranous bone formation which causes abnormalities in the clavicle, cranium and pelvis. This is a condition inherited in which 1/3 of the patients show spontaneous mutation and 2/3 show familial variation. Gene RUNX2 plays a key role in the regulation of chondrocyte differentiation during endochondral bone formation. This new principal gene may explain the underlying mechanisms of bone formation in addition to the pathobiology of cleidocranial dysostosis. According to the mentioned above, an aim of our survey was to describe of cleidocranial dysostosis symptoms caused by mutation in recent found RUNX2 gene.

The responsible gene RUNX2 (Runt-related transcription factor 2) is a cloned gene located on the short arm of chromosome 6 which activates osteoblast differentiation as an osteoblastic-specific transcription factor and regulator which controls the differentiation of precursor cells in osteoblasts. The cells secrete bone matrix and thus form a bone. The affected children have a small face but a big head (the skull is bigger than usual but the face is smaller), the eyes are slightly wider, the palate is high and narrow, deciduous teeth emerge normally but the eruption of permanent teeth are delayed and imperfect and supernumerary teeth are present 65%. The shoulders are low and the thorax looks narrow, thus leading to respiratory problems in the newborn. Anomalies in the sternum are due to abnormal intramembranous ossification and pectus excavatum is a prevailing condition. One or both of the clavicles may show growth deficiencies and they may be totally absent. Most common defect is the absence of the lateral end of the clavicle, followed by the growth failure of the middle 1/3 of the clavicle. The defect can be palpated. As a result of hypermobility in bilateral cases, the shoulders may come in contact with each other before the chest. The scapula may look smaller and the wings may be noticeable. Patients with cleidocranial dysostosis are short, the mean height in adult men is between the 5th and 50th percentile of height

for their age, whereas in women dwarfism is more apparent and the mean height is below the 5th percentile of height of their peers.

In conclusion, cleidocranial dysostosis may lead to complications such as scoliosis and kyphosis concurrent with various orthopedic involvements due to skeletal dysplasia. Since concurrent spinal deformities are of progressive nature, as in these cases, surgical treatment may be necessary.

Abdalla Bahdar, Olga Kushniryk
**HEPATITIS C: TRANSMISSION AND METHODS OF
LABORATORY DIAGNOSIS**

*Higher State Educational Establishment of Ukraine
“Bukovinian State Medical University”, Chernivtsi, Ukraine*

Hepatitis C is inflammation in the liver caused by virus C which results the patient to go through the following symptoms: feeling very tired, sore muscles, joint pain, fever, nausea or poor appetite, stomach pain, itchy skin, dark urine, a yellow discoloration of the skin and whites of the eyes, called jaundice. Over 3% of the world's population are infected with HCV: 4 million in Europe and 3.2 million in the United States. Many people are not aware of hepatitis C because no symptoms are present. According to that, an aim of our review was to describe common ways of hepatitis C infection and specific methods of its diagnosis.

Hepatitis C is transmitted in several ways, including: injecting drugs or using false or unsafe injections, by transplanting organs or transferring contaminated blood from a donor to a healthy person, acupuncture injuries within the scope of health care, birth of a fetus from mother with HCV. In every four cases of 100 cases of an HCV-infected mother, an infected fetus is born, HCV may spread through medical treatment or dental treatment if the necessary precautions are not taken. The mother who is infected with the disease must refrain from breastfeeding her child if there are any cracks, sores or bleeding in the breast. Most people do not have any symptoms. Meanwhile, many people suffer from chronic liver disease and may range from mild to severe including cirrhosis and liver cancer.

Chronic liver disease develops slowly without any obvious symptoms and can be detected through routine examination. The condition is not limited to the liver in a small proportion of patients due to its response to

the body's immunity to HCV infection. These include diabetes, renal glomerulonephritis, and lymphoma. Hepatitis C is diagnosed by blood test and by specific antibodies to HBV and antibodies 4-10 weeks after infection. Diagnosis may be wrong and you must undergo additional tests to confirm. Such as a PCR test to detect viral RNA. Sometimes the diagnosis is sinful when the proportion of antibodies is too low to be detected. Undergo a quality test to investigate the presence or absence of HCV RNA. HCV RNA appears 2-3 weeks after the disease. Undergo a quality test to detect the number or diameter of the RNA virus. The presence or absence of chronic liver disease should be diagnosed in people with HCV.

In conclusion, HCV is an important disease that rapidly spreads and awareness should be spread to eliminate it. Diagnosis should include testing and severity of liver disease, as well as the need for HBV and HAV vaccination. Hepatitis C patients are treated with antivirals.

Aadesh Upadhayay, Olga Kushniryk

CLINICAL MANIFESTATION OF ELEPHANTIASIS DISEASE

Higher State Educational Establishment of Ukraine

“Bukovinian State Medical University”, Chernivtsi, Ukraine

Lymphatic filariasis is a major cause of clinical morbidity and is an impediment to socioeconomic development. Lymphatic filariasis impairs the lymphatic system and can lead to the abnormal enlargement of body parts, causing pain, severe disability and social stigma. More than 856 million people in 52 countries like Africa, India, Asia, the Pacific islands, and South and Central America worldwide remain threatened by lymphatic filariasis and require preventive chemotherapy to stop the spread of this parasitic infection. In this regard, an aim of our paper was to review the frequency of filariasis clinical manifestation, particularly elephantiasis, in the world.

In 2000 over 120 million people were infected, with about 40 million disfigured and incapacitated by the disease. The global baseline estimate of people affected by lymphatic filariasis was 25 million men with hydrocele and over 15 million people with lymphoedema. At least 36 million people remain with these chronic disease manifestations. Lymphatic filariasis is caused by infection with parasites classified as

nematodes of the family Filariodidea: *Wuchereria bancrofti* (responsible for 90% of the cases), *Brugia malayi* (causes most of the remainder of the cases) and *Brugia timori*. Adult worms lodge in the lymphatic vessels and disrupt the normal function of the lymphatic system. Morbidity management and disability prevention are vital for improving public health and are essential services that should be provided by the health care system to ensure sustainability. Mosquito control is a supplemental strategy supported by WHO. It is used to reduce transmission of lymphatic filariasis and other mosquito-borne infections.

Thus, 499 million people no longer require preventive chemotherapy due to successful implementation of WHO strategies. Elimination of lymphatic filariasis is possible by stopping the spread of the infection through preventive chemotherapy.

Kozariichuk N.Ya.

ANATOMIC PECULARITIES OF THE OCULOMOTOR NERVE IN THE EARLY PERIOD OF HUMAN ONTOGENESIS

Higher State Educational Establishment of Ukraine "Bukovinian State Medical University", B.L. Radzikhovskiy Department of Ophthalmology Chernivtsi, Ukraine

The embryology of the third cranial nerve, especially its peripheral development, has received little attention in human in comparison to the important role it plays in postnatal life. According to Mann, 35 week 8 witnesses the first appearance of the oculomotor nucleus, which consists of 2 groups of cells on either side of the midline in the basal plate of the mesencephalon.

The specimen of 20 pre-fetus were selected to be the materials of the research. Following investigational methods have been used: microscopy of consecutive histological section seriesconventional and thin preparations, macroscopy .

In a10.0 mm embryo, neuroblasts begin to aggregate along the somatic efferent column. The caudal group, which constitutes the trochlear nucleus and the cephalad group becomes the oculomotor nucleus.

A complete separation appears at 13.0 mm (40-day) stage and cell processes from the cephalad group begins downward to emerge from the ventral surface of the mesencephalon. They aggregate to form the

oculomotor nerve, and become associated with Schwann cells derived from the neural crest. In pre-fetuses 19 - 50 mm the oculomotor nerve becomes to differentiate on the ipsilateral side to the muscles they will innervate. The cell bodies constituting the subnucleus for the superior rectus muscle migrate to the contralateral side, but project their axons across the midline. Proximally the peripheral nerve fibers finally make contact with their muscles of innervation at the 26 mm (7-week) stage. Initially, undifferentiated nerve endings divide and ramify around the early myoblasts, forming a fine net. During the 54–61 mm (11–12-week) stages many of these fine branches degenerate.

Specialized nerve endings are first seen beginning in the 68 mm stage, and by the 80 mm (14-week) stage specific motor and sensory fibers will become distinguished. Myelination of the oculomotor nerve trunk commences at about the 90 mm (15-week) fetal stage, but does not begin in the intramuscular component of the nerve until term. Myelination occurs after birth. Sympathetic fibers are not seen in the muscle until the 165 mm (22-week) stage, associated with the developing arterioles

Yemelyanenko N. R., Banul B.U.

BLOOD SUPPLY OF THE NASAL SEPTUM IN THE EARLY CHILDHOOD

Higher State Educational Establishment of Ukraine, Department of Human Anatomy "Bukovinian State Medical University", Chernivtsi

Diameter of vessels front and back latticed arteries fluctuate from 0.28 to 0.38mm. The amount of branches of the second order is 2 (lateral and medial), branches of the third order – from 5 to 7.

Diameter of the last equals 0.08-0.1 mm. Wedge-shaped artery in six cases (20%) gave 4, in two (5%)-3 and in five (15%) -2 rear lateral nasal branches. Their diameter fluctuates from 0.36 to 0.4 mm. Mentioned branches ramify, mainly, in the region of lower and medium nasal sink and correspondent nasal passage, where they form loops of different shape and magnitude.

Wedge-shaped artery enters through the wedge-shaped aperture into the rear area of the nose, where gives away rear artery of the nasal septum to the nasal septum. Rear artery of the nasal septum has horizontal direction, enters into the back region of the nasal septum, where dichotomically (zootomically) divides into two branches of the second order: upper and lower.

Upper travels to the front, divides into tertiary branches, which anastomose with rear latticed arteries. Lower is detected to be closer to the lower edge of the nasal septum.

The biggest concentration of the lattice of the arterial vessels is observed in the front lower part of the nasal septum, where ramify mainly stems of the anterior latticed artery and their anastomoses with rear latticed artery and rear artery of the nasal septum.

Topographically the most superficially located small mesh of blood vessels, and then vessels of the average calibre and most deeply are founded large trunk vessels.

Yemelyanenko N. R., Banul B.U.

INNERVATION OF NASAL SEPTUM IN THE EARLY CHILDHOOD

Higher State Educational Establishment of Ukraine, Department of Human Anatomy "Bukovinian State Medical University", Chernivtsi

Bone part of the nasal septum creates ploughshare, which is presented by one bone plate. On the back edge of the lamella more expressed wings are detected, which adjoin to the body of a sacrum (wedge-shaped bone).

Front-end size of a ploughshare reaches 30.2 ± 0.6 mm, vertical 11.2 ± 0.13 mm. Front-end size of the bone plate in objects of early childhood makes 39.0 ± 0.5 mm, the biggest vertical size is 24.0 ± 0.4 mm. Thickness of cartilaginous plate equals 2.4 ± 0.05 mm, and together with mucous membrane it makes 3.2 ± 0.13 mm. On 8 preparations (30%) in foreground section of the nasal septum blind channel is detected, which is called Jacobson's organ.

Research of the nerves showed that mediocre upper rear nasal branches penetrate into the back sections of the nasal septum, which start from the winged knot and are detected in its mucous membrane. Nasopharyngeal nerve travels in the ascending direction, branching out into moderate branches in the mucous membrane of the septum. In the thickening places of mucous membrane of nasal septum, nerve fibres almost perpendicularly heading to the epithelial lining.

Superficially located are glands and small vessels, then nerves and vessels of the average calibre and deep down-large nerve trunks and vessel stems.

Yemelyanenko N. R., Banul B.U.

INCIPIENCE OF THE NASAL SEPTUM IN NEWBORN AGE

Higher State Educational Establishment of Ukraine, Department of Human Anatomy "Bukovinian State Medical University", Chernivtsi

Cartilaginous part of the nasal septum forms homogeneous cartilaginous tissue and to differentiate cartilage of the proper nasal septum from perpendicular plate of the latticed bone in newborns is impossible. Bone part of the nasal septum is formed by ploughshare, which is presented by two clearly expressed bone plates. The rear ones begin near lower back edge of the nasal septum, turning upwards and cover lower edge of the rear part of the uniform cartilaginous plate of the nasal septum. Their upper rear ends adjoin to front of the lower surface of the body of the wedge-shaped bone. Rear front size of the ploughshare is 27.0 ± 0.26 mm, vertical – 9.1 ± 0.05 mm. Longitudinal size of the nasal septum in newborns is 35.0 ± 0.6 mm, the largest vertical size – 19.0 ± 0.14 mm. Thickness of the cartilages plate of the nasal septum equals 1.7 ± 0.07 mm, together with mucous membrane – 3.0 ± 0.2 mm.

In the thickening of lower frontal section of mucous membrane of nasal septum situated mainly clusters of secretory glands. In the olfactory area of lateral wall and nasal septum detected olfactory cells, processes of which head upwards, joining into thin threads, and near the porous plate – into bigger trunks.

On 10 preparations (35%) in lower front section of the nasal plate small concavity is detected, which continuous into the blind channel. Histological research of the last one has confirmed the presence of the Jacobson's organ.

Yemelyanenko N. R., Banul B.U.

TOPOGRAPHICALLY ANATOMICAL SPECIALITIES OF THE NASAL SEPTUM IN THE SECOND PERIOD OF THE CHILDHOOD

Higher State Educational Establishment of Ukraine, Department of Human Anatomy "Bukovinian State Medical University", Chernivtsi

Due to the research of the biological preparations of the second period of childhood (8-12 years old) it is defined that cartilaginous part of the

nasal septum is formed by cartilage of the nasal septum and bone tissue of the perpendicular plate of the lattice bone.

Glands of the mucous membrane are found at the larger distance in comparison to previous age period. Blood supply occurs due to front and rear latticed arteries and wedge-shaped artery. Diameter of the vessels of the nasal cavity walls of front and rear lattice arteries are enlarging.

In the rear areas of the nasal septum penetrate medium upper posterior nasal branches, which begin from winged knot and are detected in its mucous membrane. Nasal palatine nerve heads in downward direction, branches out into small branches in mucous membrane of the nasal septum. All main nerve stems in diameter of 0.46-0.5 mm are situated in deep layer of the mucous membrane, where they divide into secondary and tertiary branches.

In the areas of thickening of the mucous membrane of the nasal septum, nerve fibres almost perpendicularly travel to the epithelial lining.

Topographically most superficially are located glands and small grid blood vessels, then nerves and vessels of the average calibre and the deepest-are large trunks of nerves and vessels.

Yemelyanenko N. R., Banul B.U.

TOPOGRAPHICALLY ANATOMICAL SPECIALITIES OF THE NASAL SEPTUM IN PRIMARY PERIOD OF THE CHILDHOOD

Higher State Educational Establishment of Ukraine, Department of Human Anatomy "Bukovinian State Medical University", Chernivtsi

The research of the biological preparations of period of primary childhood (4-7 years old) has established that cartilaginous part of the nasal septum forms homogeneous cartilaginous tissue and to differentiate proper cartilage of the nasal septum from perpendicular plate of the lattice bone is still impossible. Front rear size of the ploughshare reaches 31.0 ± 0.24 mm; vertical- 12.0 ± 0.1 mm. Front rear size of the nasal septum enlarges to 43.0 ± 0.8 mm, the largest vertical size-to 28.0 ± 0.7 mm.

Blood supply takes place due to frontal and rear latticed arteries and wedge-shaped artery. Diameter of the vessels' walls of the nasal cavity-front and back latticed arteries almost unchanged.

Into the backward sections of the nasal septum penetrate middle upper posterior nasal branches from the wing-palatine node, which are

detected in its membrane. Nasal palatine nerve travels in downward direction, ramifies into moderate branches in the mucous membrane of the septum.

Topographically most superficially located are glands and small grid blood vessel, then nerves and vessels of the average calibre and the deepest – are large trunks of nerves and vessels.

Banul B.U., Yemelyanenko N.R.

THE LENGTH CHANGING OF THE UTERINE TUBES IN HUMAN FETUSES

Higher State Educational Establishment of Ukraine, Department of Human Anatomy "Bukovinian State Medical University", Chernivtsi

In fetuses 100,0-110,0 mm parietal-coccyx length the right uterine tube is on the border between the large and large pelvis, covered with a peritoneum on all sides. The total length of the right uterine tube is 7,5-0,2 mm, the left uterine tube reaches 7,4-0,5 mm. In fetuses 112,0-115,0 mm parietal-coccyx length the right uterine tube is located in the cavity of a large pelvis. The total length of the right uterine tube reaches 9,4-0,5 mm, the left uterine tube reaches 8,2-0,2 mm. In fetuses 120,0-125,0 mm parietal-coccyx length the total length of the right uterine tube is 9,6-0,4 mm, the left uterine tube has a length of 8,5-0,5 mm. In fetuses 137,0-139,0 mm parietal-coccyx length , the total length of the right uterine tube is 12,0-0,05 mm, the total length of the left uterine tube is 10,8-0,5 mm. In fetuses 142,0-144,0 mm parietal-coccyx length , the total length of the right uterine tube is 12,6-0,05 mm, and the left-11,3-0,5 mm, and in fetuses 155,0-158,0 mm parietal-coccyx length the right uterine tube has a length of 16,5-0,05 mm, the left uterine tube - 14,2-0,5 mm. In fetuses 160,0-162,0 mm parietal-coccyx length the length of the right uterine tube reaches 16,9-0,02 mm, the left uterine tube has a length of 14,6-0,5 mm. In fetuses 165,0-167,0 mm parietal-coccyx length the right uterine tube length is 16,9-0,5 mm, and the left uterine tube reaches 14,6-0,5 mm in length. In fetuses 170,0-172,0 mm parietal-coccyx length the right uterine tube has length of 17,4-0,1 mm, the left uterine tube - 14,9-0,5 mm, in fetuses 175,0-1,77,0 mm parietal-coccyx length the right uterine tube is 17,5-0,02 mm in length, the left uterine tube is - 15,1-0,5 mm in length. In fetuses 180,0-182,0 mm parietal-coccyx length the right uterine tube is

17,6-0,5 mm long, the left uterine tube has a length of 15,3-0,05 mm. In fetuses 183,0-184,0 mm parietal-coccyx length the right uterine tube reaches 17,7-0,5 mm in length, the left uterine tube is - 15,5-0,5 mm in length. Consequently, it can be assumed that during the fetal period of human ontogenesis the length of the uterine tubes is gradually increasing.

Banul B.U., Yemelyanenko N.R.

DEVELOPMENT OF STRUCTURAL ELEMENTS OF THE SKIN IN THE AREA OF THE FACE IN THE PRENATAL PERIOD OF HUMAN ONTOGENESIS

*Higher State Educational Establishment of Ukraine, Department of
Human Anatomy "Bukovinian State Medical University", Chernivtsi*

At the end of the embryonic period of a human ontogenesis embryo is covered by one layer of epithelial cells in the area of the face. In the future, in functionally different areas of the face, the development and differentiation of structural elements of the skin occurs unevenly.

In preplants 30,0-52,0 mm parietal-coccyx length epidermis is predominantly single-layered. Intensive growth and formation of structural elements of the skin occurs in the first half of the fetal period of human ontogenesis. In fetuses 110,0-120,0 mm parietal-coccyx length fibrous dermal framework is not formed yet, cells of mesenchyma are placed loose, do not have a certain orientation. During this period, the rudiments of glands and hair appear.

In 5 months fetuses the skin becomes definitive. The thickness of the epidermis reaches 28-26 microns, the thickness of the dermis is 500-600 microns. The thickest is the layer of skin on the lips, the most subtle - on the wings and the tip of the nose.

In the second half of the fetal development, intensive development of subcutaneous adipose tissue, which develops unevenly in different parts of the face, is marked. In 7 months fetuses of fetal development, the fiber layer in the area of the forehead and cheeks is 5,0 mm, while in other areas of the face – 0,5-0,8 mm. During the fetal development, there are local and individual peculiarities of skin morphogenesis.

Banul B.U., Yemelyanenko N.R.

FEATURES OF OVARIAN DEVELOPMENT IN HUMAN FETUSES

Higher State Educational Establishment of Ukraine, Department of Human Anatomy "Bukovinian State Medical University", Chernivtsi

Right and left ovaries of fetuses 136,0-185,0 mm parietal-coccyx length are located over the uterine tubes. Tubular ends of ovaries tight fit to the funnels of uterine tubes. Their length is 8,1-0,2 mm. The ovaries are fusiformed and flattened in anterior-posterior direction. There is distinguished anterior and posterior surface in ovaries, superior rounded and inferior sharpened edges. Rounded end of uterine adheres to the posterior uterine surface.

The length of right and left ovaries of fetuses 137,0-139,0 parietal-coccyx length reaches 9,2-0,5 mm. The ovaries are located over the uterine tubes. They are triangular, obliquely placed. There is distinguished in ovaries anterior, superior and posterior-inferior surfaces; superior, inferior and posterior edges. Tubular and uterine ends of ovaries are rounded.

In fetuses 142,0-162,0 mm parietal-coccyx length the ovaries adhere to the superior surface of uterine tubes and their mesenteries.

In fetuses 165,0-167,0 mm parietal-coccyx length the uterine end of ovary is located behind the isthmus, which is immersed in rectum uterine concavity. The ovaries are located behind the uterine tubes and tight fit to them.

In fetuses 175,0-177,0 mm parietal-coccyx length. There are distinguished five narrowing along the uterine tubes, right and left ovaries are located obliquely in the cavity of large pelvis over the uterine tubes.

In fetuses 180,0-184,0 parietal-coccyx length the front leaf of mesentery of the uterine tubes goes into the ovarian gates, wherefrom the peritoneum heads to the top and covers iliac vessels and ovulatory hangers. Left and right ovaries are located horizontally over the uterine tubes. During the fetal period ovaries change in size, shape and location concerning the uterine tubes.

Banul B.U., Yemelianenko N.R.

**MORPHOLOGY OF THE WALLS OF THE LARGE INTESTINE
IN THE EMBRYONIC PERIOD OF HUMAN ONTOGENESIS**

*Higher State Educational Establishment of Ukraine, Department of
Human Anatomy "Bukovinian State Medical University", Chernivtsi*

In the 6th week germs of fetal development, the lumen of the large intestine is narrow, in some areas it is absent. The cytoplasm of the epithelial cells has a different shape, the nuclei become oval. The layer of mesenchymal cells is much thicker than the epithelial layer. Mesenchyma of the posterior gut is not differentiated. The mesenchyma in the area of the erythema is covered by an unformed mesothelium. In the embryo at 7 weeks, the cells of the mesenchymal layer begin to decompose, especially in the rectum. The mesenchyma is divided into two parts: a loose bow, inside and a compact - located from the outside. The cells of the outer layer are more differentiated. Epithelial folds appear in the gut of the 8th week of fetal development in the rectum. At this stage, it is possible to observe in the lumen of the colon the accumulation of mucus. The multi-row epithelium of the mucous membrane is clearly distinguished from the mesenchymal layer. Under the endodermal layer, two layers are observed: the intermediate and the outer. Intermediate - consists of loose cells. The outer layer subsequently forms a submucosal layer. In the embryos of this stage there is a differentiation of the serous membrane of the rectum. Mesenchymal cells of this shell are oval and stem-like, and there is also a laying of a circular masonry layer. At the 9th week of fetal development, crypt appears in the rectum, and later they can be seen in the intestine and appendix. The intestine wall thins, the villi appear, covered with a single-layer prismatic epithelium. Between the cells of the villi and folds is a large number of glass-shaped cells. There is a further differentiation of mesenchyma. Circular masonry layer thickens, there is a tab of a longitudinal masonry layer. In the germs of the 3-months, along the thick intestine, the mucous membrane is well defined. Enlightenment and separate layers of the large intestine are not the same in different parts of it.

Banul B.U., Yemelyanenko N.R.
**DEVELOPMENT OF UTERINE TUBES AND THEIR
STRUCTURES AT THE BEGINNING OF THE FETAL PERIOD
OF HUMAN ONTOGENESIS**

*Higher State Educational Establishment of Ukraine, Department of
Human Anatomy "Bukovinian State Medical University", Chernivtsi*

Parietal-coccyx length of fetus 81,0-135,0 right uterine tube is located in the cavity of the large pelvis and covered with a peritoneum on all sides. The length of uterine tube is 13,5-0,2 mm, the funnel -2,3-0,05 mm, the ampule is -6,0-0,05 mm, the isthmus is -3,0-0,01 mm. The width of the funnel is -2,0-0,02 mm, the ampule is -2,0-0,05 mm, the isthmus is -1,8-0,01 mm. Mesentery of the uterine tube is 4,9-0,1 mm long, the width is -2,1-0,01 mm. The mesentery is formed by two leaves of peritoneum which pass to the parietal peritoneum walls of the large pelvis without distinct contours. It is determined one narrowing along the tube which is located on the verge between the ampules and isthmus. The tube has a vertical direction and it is located in front of the right umbilical artery. Thorns of the tube look like tubercles and interfere with external iliac vessels. Left uterine tube is located in the cavity of the large pelvis and covered with a peritoneum on all sides. The length of the uterine tube is 11,3-0,5 mm, the funnel is -2,1-0,05 mm, the ampule is -5,5-0,3 mm, the isthmus is -3,5-0,01 mm. The width of the funnel is -3,0-0,02 mm, the ampule is -2,5-0,01 mm, the isthmus is -1,8-0,01 mm. The length of the mesentery of the uterine tube is 6,2-0,02 mm, the width is -2,1-0,05 mm. The mesentery is formed by two leaves of the peritoneum which pass to the parietal peritoneum walls of the large pelvis without distinct contours. There is determined two narrowings along the tube: one of them is between the ampule and isthmus, another one is between the funnel and the ampule. The uterine tube has a vertical direction and it is located on the anterior surface of the left umbilical artery, the funnel with the thorns of the tube is located in front of external iliac vessels. The length of right ovaries is between 6,9-10,8, while the left ovaries is between -6,5-10,2 mm. The distance between the uterine tubes abreast the bottom of the uterus is 2,1-0,05 mm. The uterus is flattened abreast the bottom, the corpus and the isthmus has cylindrical shape. The bottom and the corpus is located in the cavity of the large pelvis, while the isthmus is in the cavity of the small pelvis.

3MICT

Aleksandrova K.V., Mykhalchenko E.K., Vasylyev D.A. ENERGOTROPIC PROPERTIES OF 7-SUBSTITUED DERIVATIVES OF 3-BENZYL-8-PROPYLXANTHINES AS POTENTIAL ORGANOPROTECTIVE DRUGS	3
Bambuljak A.V., Boichuk O.M. SURGICAL FEATURES OF FRONTAL SINUSES	4
Boichuk O.M., Bambuljak A.V. EWING’S SARCOMA	5
Dmytrenko R.R., Honcharenko V.A. PERIODONTAL DISEASES – MODERN PROBLEM STATE.....	6
Kavun M.P. THE DEVELOPMENT OF THE HEPATO-DUODENAL LIGAMENT IN THE 6 – 10 MONTHS HUMAN FETUSES.....	7
Kavun M.P. MORPHOGENESIS OF THE HEPATO-DUDENAL LIGAMENT IN THE 3 – 5 MONTHS HUMAN FETUSES.....	8
Kushnir O.V., Fundiur N.M., Grachova T.I.,Iftoda O.M. HYGIENIC EVALUATION OF QUANTITATIVE AND QUALITATIVE COMPOSITION OF THE DAILY NUTRITION RATION OF CHILDREN AT THE PRESCHOOL INSTITUTIONS OF CHERNIVTSI	9
Shvygar L.V., KhlunovskaL.Yu., PhD, MD, Associate Professor, PhD, MD, Assistant Professor STRUCTURAL CHANGES OF MYOCARDIUM IN CHILDREN WITH ARTERIAL HYPERTENSION	12
Shvygar L.V., Khlunovska L.Yu., PhD, MD, Associate Professor, PhD, MD, Assistant Professor EVALUATION OF BLOOD SUPPLY TO THE BRAIN IN CHILDREN WITH SYNDROME OF VEGETATIVE- VASCULAR DYSFUNCTION	13
Lavriv L.P. DEVELOPMENT OF THE HUMAN PAROTID GLAND IN FETUSES	14
Kostiuk V.O., Lavriv L.P., Stratiichuk S.D. INFORMATION ABOUT THE TOPOGRAPHIC-ANATOMICAL FEATURES OF THE MENTAL FORAMEN OF THE MANDIBLE	15

Nahirniak V. M. ANALYSIS OF THE INVESTIGATION OF THE REDUCTION IN PERIPHERAL VASCULAR RESISTANCE AFTER EXPOSURE OF LOW EXTREMITIES TO THE PERIODIC MECHANICAL VIBRATIONS	17
David Alexander, Nazymok Ye.V., Ivanushko Ya.G. MAIN STEPS IN CASES OF THERMAL INJURY	18
Romanenko M.I., Dolhikh O.P., Ivanchenko D. H., Sharapova T. A. SYNTHESIS, PHYSICAL, CHEMICAL AND ANTIOXIDANT PROPERTIES OF 7-ALKYL-3-METHYLBENZYL-8-AMINOGLUTARIC ACIDS DERIVATIVES	19
Sarafinyuk L.A., Khavtur V.O., Fedoniuk L.Ya., Khapitska O.P., Sarafinyuk P.V. CONNECTIONS OF RHEOVASOGRAPHY PARAMETERS OF THE HIGH WITH CONSTITUTIONAL INDICATORS IN VOLLEYBALL PLAYERS	21
Semchenko V.A., Voronych V.O. DETERMINATION OF ISCHEMIC RISK IN PATIENTS WITH MYOCARDIAL INFARCTION	23
Shcherbina I.M., Naguta L.O., Plakhotna I.Yu. CRYOGENIC FACTORS IN VIOLATION OF MENSTRUAL FUNCTION IN WOMEN OF REPRODUCTIVE AGE	25
Shcherbina M.O., Lipko O.P., Kurichova N.Yu. PATHOGENETIC ESSENCE OF CHRONIC INFLAMMATION IN UTERINE BLEEDING IN WOMEN IN THE PERIMENOPAUSAL PERIOD	26
Shcherbina M.O., Skorbach O.I., Skorbach Yu.I. NEW APPROACHES TO THE CORRECTION OF CLINICAL AND METABOLIC DISORDERS IN WOMEN AFTER HYSTERECTOMY	28
Shvets V.I., Shvets N.V. THE ROLE OF THE ADIPONINS WITH DISEASES SUCH AS OBESITY, ARTERIAL HYPERTENSION, OSTEOARTHRITIS.	29
Stoliar D.B. FEATURES OF THE STRUCTURE OF THE HUMAN TEMPOROMANDIBULAR JOINT IN THE THIRD TRIMESTER OF THE INTRAUTERINE GROWTH.....	31
Guzik O.V., Navarchuk N.M., Hresko A.S., Sribnyak A.Z. MORPHOLOGICAL PECULIARITIES OF THE JUXTAORAL ORGAN OF CHIEVITZ	32

Marchuk O., Pasichnyk A., Marchuk O. CAUSES OF TRANSIENT SYNOVITIS IN CHILDREN.....	33
Aryak Ipsit,Olga Kushniryk FREQUENCY OF BOMBAY PHENOMENON IN THE WORLD.....	35
Haba M. Y., Pavliv Kh. I., Masna Z. Z. MORPHOFUNCTIONAL PECULIARITIES OF GASTRIC MUCOSA UNDER THE OPIOID INFLUENCE	36
Herasymiuk M.I. THE USE OF DATA OF SOME MODERN LABORATORY EXAMINATION METHODS TO UPGRADE INDICATIONS FOR TUNSELECTOMY.....	38
Sorohan M.M, Pleguca O., Popova M. FEATURES OF CHANGES IN A BONE TISSUE.....	40
Guzik O.V., Navarchuk N.M., Shishela M.S., Shkvarkovska A.I. FETAL DEVELOPMENTANDMORPHOLOGICAL PECULIARITIES OF THE FACIAL NERVE.....	41
Ostapchuk V.G., Popovich V.V. MODERN VIEWS CONCERNING OCCURRENCE OF ULCEROUS DISEASE AND IMPROVEMENT OF ANTIBACTERIAL THERAPY IN CHILDREN	43
Shvets N.V., Shvets V.I., Tymofiychuk I.I. STUDY OF THE EFFECT OF ESTROGEN ON COGNITIVE FUNCTIONS IN OLD RATS AND IN THE SETTING OF DIABETES MELLITUS	44
Rusnak V.F., Soni Shivam, Singh Yaduvendra TOPOGRAPHO-ANATOMIC FEATURES OF ONTOGENESIS OF SUPRASPINATUS AND INFRASPINATUS MUSCLES OF THE POSTERIOR SCAPULAR REGION	46
Herasym L.M.,Halahdina A.A. PERINATAL TOPOGRAPHY OF THE EXTERNAL CAROTID ARTERY	47
Antoniuk O.P., Sharma Himanshu THE FORMATION OF PHYSIOLOGICAL ESOPHAGEAL ATRESIA	48
Antoniuk O.P., Kumar Amit THE PECULIARITIES OF MORPHOGENESIS OF DUODENAL ATRESIA IN NEWBORNS...	49
Antoniuk O. P., Gaudia Deepak MORPHOFUNCTIONAL CHARACTERISTIC OF THE CHANGE OF JEJUNAL STRUCTURE DURING ATRESIA.....	50

Besplitnik M.G., Rudiuk O.G. WAYS OF LETTING OF THE LYMPH FROM LUMBAR-SACRAL PLEXUS.....	52
Besplitnik M.G., Rudiuk O.G. INNATE SCOLIOTIC ILLNESS	53
Besplitnik M.G., Rudiuk O.G. FEATURES OF SPINAL DISRAPHISM	54
Kryvetskyi V.V., Besplitnik M.G. FEATURES OF VASCULARIZATION OF THE SPINE IN FETAL PERIOD AND NEWBORNS.....	55
Vepruk Yu.M., Kashperuk-Karpivk I.S., Rykhlo I.S., Prunchak V. THE ECOLOGY AND FEATURES OF HOUSEPLANTS	56
Vepruk Yu.M., Tovkach Y., Rykhlo I.S., Blahun S. THE ECOLOGY OF ROOM FLORICULTURE	57
Vepruk Yu.M., Proniaiev D.V., Rykhlo I.S., Sirochenko O. EFFECT OF XENOBIOTICS ON KIDNEY'S FUNCTIONS IN MATURE AND IMMATURE RATS UNDER CONDITIONS OF PINEAL GLAND HYPO-AND HYPERFUNCTION	59
Vepruk Yu.M., Proniaiev D.V., Rykhlo I.S. THE ROLE OF EXOGENOUS MELATONINE ON INDEXES OF RENAL FUNCTIONS UNDER THE CONDITIONS OF COMBINE INFLUENCE OF XENOBIOTICS	60
Vepruk Yu.M., Yakovets K.I., Rykhlo I.S. CHARACTERISTIC OF HOMEOSTATIC RENAL FUNCTIONS IN MATURE AND IMMATURE ANIMALS	61
Vepruk Yu.M., Kashperuk-Karpiuk I.S., Rykhlo I.S., Kozoriz V. CHARACTERIZATION OF HOMEOSTATIC FUNCTIONS OF KIDNEYS IN MATURE AND IMMATURE ANIMALS	62
Vepruk Yu.M., Tovkach Y.V., Rykhlo I.S., Pontyk M. THE IMPACT OF EXOGENOUS MELATONIN ON INDICES OF RENAL FUNCTIONS UNDER THE INFLUENCE OF COMBINED EFFECT OF XENOBIOTICS	63
Vepruk Yu.M., Tovkach Y.V., Rykhlo I.S., Stankevych K. THE IMPACT OF XENOBIOTICS ON RENAL FUNCTIONS IN MATURE AND IMMATURE RATS UNDER CONDITIONS OF PINEAL GLAND HYPO-AND HYPERFUNCTION	64

Protsak T.V., Ostapenko I.V. CONGENITAL MALFORMATION PANCREAS	65
Marchyk O.F., Protsak T.V., Hovanets K.R. THE DEVELOPMENT OF UROGENITAL SYSTEM IN HUMAN EMBRYOS	66
Tovkach Yu., Skakun A.G, Fundiur V., Paholka L. Bizer L., Zapolska O. PECULIARITIES OF MICROANATOMY OF THE UPPER JAW INJURIES IN RATS	67
Tovkach Y.V., Vepriuk Yu.M., Slobodianiuk K. PATHOLOGY OF THE CERVIX	68
Kashperuk-Karpiuk I.S., Ivancheskul A.I., Bizer L., Zapolska O. ANATOMIC FEATURES OF ELECTRONIC MICROSCOPY IN LABORATORY ANIMALS ON THE 7TH DAY AFTER A POLYTRAUMA	69
Ezhned M., Horoshko A., Matuschak M., Sakhatska I., Kostyshyn L. ESTABLISHING THE HYPOGLYCEMICEFFECT OF DANDELION AND ELECAMPANE COMBINED ROOTS EXTRACT DEPENDING ON DOSE	71
Horoshko A., PERSPECTIVES OF THE QUERCETIN DRUGS USE IN MEDICINE	72
Marchyk F.D., Protsak T.V., Trykur V.S. EMBRYOGENESIS OF URINARY SYSTEM IN PRENATAL PERIOD OF HUMAN ONTOGENESIS	74
Protsak T.V., Molyn L.R. THE ROLE OF FOLLOWING ACID AS A PRINT SPINA BIFIDA	75
Protsak T.V., Zabrods`ka O.S. Maykan P.O. SHORT INFORMATION ABOUT CONGENITAL MALFORMATIONS OF THE NERVOUS SYSTEM	76
Babin V., Kushnir A.M., Khodakovska O., Rynzhuk A. FEATURES OF MORPHOGENESIS AND OPTIONAL ANATOMY OF THE LOWER SHEEP IN FAMILY FOODS	77
Tkach I., Karavan M.G., THE DEVELOPMENT OF JAWS	80

Proniaiev D.V., Laiuk D.I., Kudla M., Harchynska Y. INJURIES OF THE MAXILLOFACIAL AREA.....	82
Postevka Ira, Artysh Victor, Yuzefovich Valeri, Dutka Liliia INJURIES TO THE UPPER JAW AND RESTORING THE MUSCLE -BONE SYSTEM AFTER INJURY.....	84
Tovkach Yu.V., Didkivska A.R.,Voloshun V.L. CHARACTERISTICS OF THE FRACTURES OF THE BONES OF THE MAXILLOFACIAL AREA	85
Tovkach Yu.V., Pavlik A.L., Malyshevsky I., Shumko B, Unhurian V., Savchuk R. ATROPHY OF THE BONE TISSUE OF THE JAW IS ITS RECOVERY.....	86
Marchyk I.V., Protsyuk D. I., Staroverskaya O. O., Staroversky A. V. Minimal invasive techniques of preparation (tunnel preparation, slot-making, bate cave-making, ART-technique).....	87
Maxymiv O., Stolets A., Yakovec K. HEALTHY LIFESTYLE IN THE PRESENT.....	89
Andriyets M.M., Kyzuk F.V., Smoliak I., Buhaj I., Kozak M., Kozak Y. HEALTHY LIFESTYLE STUDENT YOUTH	90
Andriyets M., Andriyets V., Ungyrian A. SPORT IN HUMAN LIFE ..	92
Shkvarkovskaya Natalia, Shkvarkovsky Igor, Shvab A.M., Cherney Anastasia TREATMENT OF FRACTURES OF LONG BONES	93
Tovkach Yu.V., Vepriuk Yu.M., Shulgina V., Klantyuk Y.M., CRITICAL STAGES OF MAXILLA ONTOGENESIS DEVELOPMENT IN FETUS	94
Vakarchuk A., Bocharov A.V., Mendel A.O., Tovkach Yu.V. PECULIAR FEATURES OF ESOPHAGUS ULTRASOUND ANATOMY AND THE GASTRIC TRANSITION IN CHILDREN	95
Kashperuk-Karpiuk I.S., Vepriuk Yu.M., Holubiak Y., Holban V TUMOROUS AFFECTIONS OF THE OVARIES	96
Boiko V.V., Zamiatin P.N., Kizuma P. Treatment of hyperesthesia of hard tissues of teeth	97
Tovkach Yu.V., Kobyalko A.D., Yakovets K.I. ANTI-REFLUX SURGICAL APPROACH.....	99

Vepruk Yu.M., Uzintskui E.S. DEVELOPMENT OF TONGUE IN HUMAN ONTOGENESIS.....	100
Tsurkan I.M., Shumko B.I., Romaniuk H. THE ACUTE CORONARY SYNDROME AS A MANIFESTATION OF THE ISCHEMIC HEART DISEASE.....	101
Vlasova K.V., Bulyk R.Ye., Davydenko I.C., Smetaniuk O.V., Yosypenko V.R. DIURNAL VARIATIONS OF CYTOMETRIC PARAMETERS OF HYPOTALAMIC SUPRAOPTIC NUCLEUS NEUROCYTES IN RATS UNDER STRESS CONDITIONS	103
Yasynskiy M.M., Ozhogan Z.R., Belikov O.B. RESULTS OF THE STUDY ON THE TAXONOMIC COMPOSITION OF THE GUM MUCUS SURFACE MICROBIOTA IN PATIENTS WITH PARTIAL LOSS OF TEETH.....	104
Zhyrulyk Y.M., Chernovska N.V. DOUBLE PRION AS A PATHOGEN OF ALZHEIMER'S DISEASE	106
Chokan V.I., Zakharchuk O.I. CLINICAL SYMPTOMATOLOGY AND INSTRUMENTAL LABORATORY INDICATORS IN CHILDREN WITH TOXOCARA CANIS INVASION	107
Kryvchanska M.I., Bulyk R.Ye., Pishak O.V. DISRUPTION OF THE CIRCADIAN ORIENTATION OF RHYTHMS IN HUMAN	110
Stepanchuk V.V. EFFECTS OF CADMIUM CHLORIDE ON THE CIRCADIAN CHRONORHYTHMS OF FREE RADICAL HOMEOSTASIS IN THE LIVER TISSUE OF WHITE RATS	111
Batig V.M., Glushchenko T.A. HYGIENIC STATE OF THE CAVITY IMMEDIATELY AFTER COMPLEX TREATMENT OF PATIENTS WITH GENERALIZED PERIODONTITIS OF CHRONIC COURSE WITH PREDOMINANCE OF SYMPATHETIC NERVOUS SYSTEM.....	113
Kuchuk O., Ganchuk G., Zemliak O., Kuchuk N. CLINICAL FEATURES OF THE EYE INJURIES IN THE PATIENT OF THE REGIONAL OPHTHALMOLOGICAL TRAUMATOLOGY CENTRE.....	115
Marynychyna I.M., Pecheriaga S.V. ASSESSMENT OF BLOOD CIRCULATION IN THE SPIRAL ARTERIES IN DYNAMICS DURING I TRIMESTER OF GESTATION.....	117

Kosilova S.Ye. INVESTIGATION OF RISK FACTORS PROMOTING INTRAUTERINE GROWTH RETARDATION OF FETUS.....	118
Proniaiev D.V., Bulyk R.Ye., Proniaiev V.V. REGULARITIES OF MORPHOLOGICAL TRANSFORMATIONS IN THE VAGINA OF EARLY FETUSES.....	120
Proniaiev D.V., Bulyk R.Ye., Sovrea Alina TOPOGRAPHIC-ANATOMICAL UTERINE CHARACTERISTICS OF THE EARLY FETUSES.....	121
Zavolichna T., Zrybnieva.K. THE PROJECT MANAGEMENT ASPECTS OF CROSS-BORDER COOPERATION.....	123
Zrybnieva I., Zavolichna K. PROSPECTS OF DEVELOPMENT OF PUBLIC-PRIVATE PARTNERSHIP IN THE MEDICAL SPHERE IN THE CONTEXT OF SOCIALLY RESPONSIBLE MARKETING....	127
Babukh I., Bordeniuk Y. FORMATION OF NEW MANAGERS COMPETENCIES OF MEDICAL INSTITUTIONS IN THE CONTEXT OF REFORMING THE MEDICAL INDUSTRY ...	131
Zeyad Muhammad, Olga Kushniryk A TREATMENT FOR PERIPHERAL NERVE PARALYSIS.....	134
Ujjwal Awasthi, Olga Kushniryk GLOBAL DISTRIBUTION OF SCHISTOSOMIASIS DISEASE.....	135
Abhishek Kumar, Olga Kushniryk RECENT APPROACHES IN THE DIAGNOSIS AND TREATMENT OF NAEGLERIA FOWLERI INFECTION.....	136
Kartik Sharma, Olga Kushniryk TRANSMISSION PECULARITIES OF PTHIRUS PUBIS.....	137
Sohila Elkady, Olga Kushniryk CLEIDOCRANIAL DYSOSTOSIS CAUSED BY RUNX2 GENE MUTATION.....	138
Abdalla Bahdar, Olga Kushniryk HEPATITIS C: TRANSMISSION AND METHODS OF LABORATORY DIAGNOSIS.....	139
Aadesh Upadhayay, Olga Kushniryk CLINICAL MANIFESTATION OF ELEPHANTIASIS DISEASE.....	140

Kozariichuk N. Ya. ANATOMIC PECULARITIES OF THE OCULOMOTOR NERVE IN THE EARLY PERIOD OF HUMAN ONTOGENESIS.....	141
Yemelyanenko N. R., Banul B.U. BLOOD SUPPLY OF THE NASAL SEPTUM IN THE EARLY CHILDHOOD	142
Yemelyanenko N. R., Banul B.U. INNERVATION OF NASAL SEPTUM IN THE EARLY CHILDHOOD	143
Yemelyanenko N. R., Banul B.U. INCIPIENCE OF THE NASAL SEPTUM IN NEWBORN AGE.....	144
Yemelyanenko N. R., Banul B.U. TOPOGRAPHICALLY ANATOMICAL SPECIALITIES OF THE NASAL SEPTUM IN THE SECOND PERIOD OF THE CHILDHOOD	144
Yemelyanenko N. R., Banul B.U. TOPOGRAPHICALLY ANATOMICAL SPECIALITIES OF THE NASAL SEPTUM IN PRIMARY PERIOD OF THE CHILDHOOD	145
Banul B.U., Yemelyanenko N.R. THE LENGTH CHANGING OF THE UTERINE TUBES IN HUMAN FETUSES	146
Banul B.U., Yemelyanenko N.R. DEVELOPMENT OF STRUCTURAL ELEMENTS OF THE SKIN IN THE AREA OF THE FACE IN THE PRENATAL PERIOD OF HUMAN ONTOGENESIS	147
Banul B.U., Yemelyanenko N.R. FEATURES OF OVARIAN DEVELOPMENT IN HUMAN FETUSES.....	148
Banul B.U., Yemelianenko N.R. MORPHOLOGY OF THE WALLS OF THE LARGE INTESTINE IN THE EMBRYONIC PERIOD OF HUMAN ONTOGENESIS.....	149
Banul B.U., Yemelyanenko N.R. DEVELOPMENT OF UTERINE TUBES AND THEIR STRUCTURES AT THE BEGINNING OF THE FETAL PERIOD OF HUMAN ONTOGENESIS.....	150

Natural Science Readings